

Case report

Reversible cerebral vasoconstriction syndrome during caesarean section

Szilard Laszlo Safran,^{1,2} Christian Balmer,¹ Georges Savoldelli ^{2,3}

¹Service d'anesthésiologie et de réanimation du CHVR, Hôpital du Valais, Sion, Switzerland

²Department of Anaesthesiology, Clinical Pharmacology, Intensive Care and Emergency Medicine, Geneva University Hospitals, Geneva, Switzerland

³Department of Anaesthesiology, Clinical Pharmacology, Intensive Care and Emergency Medicine, Faculty of Medicine, University of Geneva, Geneva, Switzerland

Correspondence to

Professor Georges Savoldelli;
Georges.savoldelli@hcuge.ch

Accepted 21 November 2019

SUMMARY

We describe the case of a 25-year-old parturient who presented sudden onset and short-lived severe headache caused by reversible cerebral vasoconstriction syndrome (RCVS) during an emergency caesarean section. The syndrome was triggered by phenylephrine administered intravenously to correct arterial hypotension following spinal anaesthesia. RCVS is a clinical and radiological syndrome attributed to transient disturbance in the control of cerebral arterial tone resulting in vasospasms. The syndrome can be precipitated by several triggers, including vasoactive drugs, often used during spinal anaesthesia, illicit drugs, pregnancy and postpartum state. Diagnosis and management can be challenging during pregnancy, peripartum or post partum, since many medications commonly used during these periods must be avoided to prevent triggering RCVS. The aim of this report is to raise the awareness, particularly for anaesthesiologists and obstetricians, of this rare and potentially serious syndrome. We discuss diagnosis, triggers, pathogenesis, clinical course and complications, as well as coordinated multidisciplinary management plans.

BACKGROUND

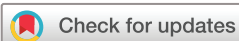Reversible cerebral vasoconstriction syndrome (RCVS) is characterised by the occurrence of acute, severe and short-lived headache associated with angiographical signs of segmental vasoconstriction of cerebral arteries. RCVS can occur without any obvious underlying cause; however, in 25%–50% of all cases, it is triggered by a known factor. In addition, various conditions, such as pregnancy and the postpartum period, are associated with an increased incidence of the syndrome.^{1,2} Interestingly, the time of onset after exposure to an exogenous trigger can be immediate or delayed by several months. In more than 50% of published cases, the most commonly reported trigger was the use of vasoactive drugs and the postpartum state.³

In the case we describe here, the patient developed a 'thunderclap headache', which is a typical symptom of RCVS, after the administration of a bolus of phenylephrine, which is a potent vasoactive drug. To our knowledge this is the first report of a patient who presented a RCVS during caesarean section while under spinal anaesthesia. The occurrence of the symptoms immediately after the administration of atropine and phenylephrine is striking.

CASE PRESENTATION

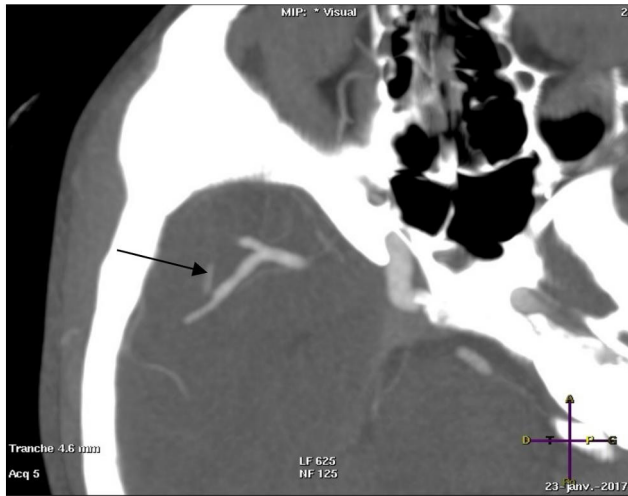A 25-year-old healthy woman was admitted at 39 weeks' gestation for spontaneous onset of labour with foetal presentation in the breech position. Her medical history was uneventful except for a previous miscarriage occurring in the first trimester. She was 158 cm tall and weighed 59 kg. Physical examination, vital signs and laboratory results were all in the normal range. An urgent category 2 caesarean delivery under spinal anaesthesia was planned.

Spinal anaesthesia was performed in the left lateral position, using a 24-gauge spinal needle at the L3–4 interspace, with 10 mg hyperbaric bupivacaine and 25 mcg fentanyl. An intravenous fluid co-loading of 1000 mL Ringer's solution was running in parallel. The patient was then placed in the supine position with left lateral table tilt, and typical sensorimotor block at T6 level appeared within a few minutes. Shortly after the onset of anaesthesia the patient presented severe bradycardia and hypotension (pulse 35 bpm and unmeasurable blood pressure). This prompted the intravenous administration of 0.5 mg Atropine and 100 mcg phenylephrine. Shortly thereafter, a sinus tachycardia at 140 bpm and a systolic blood pressure of 180 mm Hg were observed. Concomitantly, the patient described the sudden onset of severe headache without associated focal neurological symptoms. She characterised the headache as 'the worst she had ever experienced'. The hypertension and the headache responded well to the administration of small boluses of 20 mcg of intravenous nitro-glycerine (total of 60 mcg). After a rapid return of blood pressure to the normal range, the surgery was carried out uneventfully. A healthy female baby (2830 g; Apgar scores of 9/9/10) was delivered. At the end of the surgery, the patient's vital signs were stable and all within the normal range. The headache was still present but bearable during a normal neurological examination in the recovery room. An urgent cerebral CT angiography was performed and revealed images compatible with RCVS of the right Sylvian and right anterior cerebral artery (see [figure 1A,B](#)). A few hours after surgery, the headache disappeared completely. Patient's follow-up by a neurologist and neurovascular ultrasound confirmed complete resolution of vasospasms in the cerebral arteries. The patient was discharged from the hospital after 5 days with instructions to consult immediately should the symptoms reoccur. Two weeks after discharge, follow-up consultation with a neurologist, including a neurovascular ultrasound, was unremarkable.

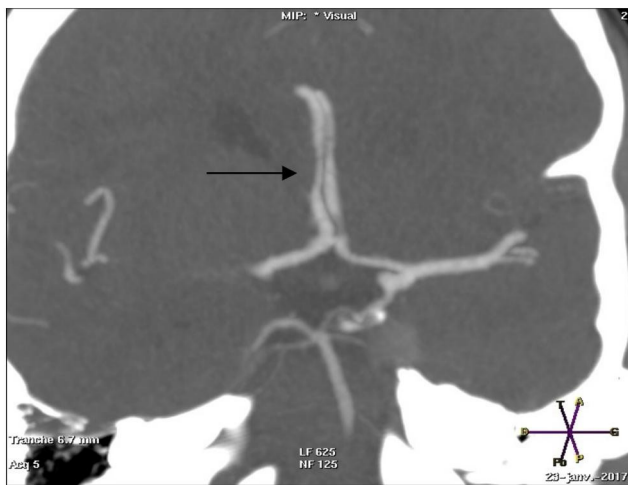


© BMJ Publishing Group Limited 2019. No commercial re-use. See rights and permissions. Published by BMJ.

To cite: Safran SL, Balmer C, Savoldelli G. *BMJ Case Rep* 2019;**12**:e230606. doi:10.1136/bcr-2019-230606



A



B

Figure 1 A and B Cerebral CT angiography showing spasm (arrows) of the right Sylvian (1A) and right anterior cerebral artery (1B) compatible with a reversible cerebral vasoconstriction syndrome.

OUTCOME AND FOLLOW-UP

Six months after the caesarean section, the patient had not experienced subsequent headaches. She was living a normal life without associated neurological symptoms. She has been given a list of medications and drugs that must be strictly avoided (see table 1). The communication of this list was considered particularly important, as several listed items are over-the-counter products, including nasal vasoconstrictors, non-steroidal anti-inflammatory drugs and medicinal herbs. The patient is aware that, in case of a future pregnancy, a careful follow-up and planning of the delivery by a multidisciplinary medical team will be necessary.

DISCUSSION

The earliest clinical reports of RCVS (from the 1960s) associated the presentation of the syndrome with a ‘thunder-clap headache,’ use of vasoactive drugs, postpartum state, un-ruptured cerebral aneurysm and migraine headaches.⁴ The syndrome has been described in the medical literature for individuals aged from 10 to 76 years,^{5 6} with the highest frequency at approximately 42 years. The syndrome is more frequent in woman, with no limitation to any single ethnic or racial group.^{4 6 7} RCVS is a rare cause of secondary headache, and some recent reports have suggested that the incidence might be increasing. Improved physician awareness and diagnostic/imaging techniques may be contributing to a ‘false’ increase.^{6 8} The pathophysiology of RCVS is not clearly understood. The proposed pathogenesis is a transient failure of the regulation of cerebral arterial tone, in which sympathetic over-activity, endothelial dysfunction and/or oxidative stress seem to play a role in its development.^{9 10}

In most cases, RCVS has a good prognosis, although serious complication can occur. Ducros *et al*,^{3 7 8 11} in a review and in three large case series, noted that cortical subarachnoid haemorrhage was present in 30%–34% of RCVS patients, focal neurological deficits in 8%–43%, seizures in 1%–17%, cerebral infarction in 6%–39%, and posterior reversible encephalopathy syndrome (PRES syndrome) in 9%–38%. Focal neurological deficits found in RCVS include hemiplegia, dysarthria, aphasia, ataxia, numbness, visual deficits and cortical blindness. These findings may be transient or permanent. The presence of neurological deficits that do not improve within 24 hours likely reflects the sequelae of ischaemic infarct.¹² The most common

Table 1 Drugs and clinical entities associated with reversible cerebral vasoconstriction syndrome

I. Precipitants encountered during pregnancy, peripartum and postpartum states

Related to pregnancy and postpartum states	Pre-eclampsia, eclampsia, HELLP syndrome
Vasoactive medications	Alpha-sympathomimetics, phenylephrine, pseudoephedrine, ephedrine, norepinephrine, phenylpropranolamine
Ergot alkaloid derivatives	Ergotamine, bromocriptine, methergine, lisuride
Vasoactive recreational/illicit drugs	Cocaine, ecstasy, cannabis, marijuana, lysergic acid diethylamide, (meth)-amphetamines, nicotine, alcohol
Antidepressants	Monoamine oxidase inhibitors, selective serotonin re-uptake inhibitors
Other drugs	Triptans, interferon, non-steroidal anti-inflammatory drugs, diet pills, herbal medications, such as ginseng

HELLP, Hemolysis, Elevated Liver enzymes, Low Platelet count.

II. Other precipitants and associated clinical entities

Catecholamine-secreting tumours	Pheochromocytoma, paraganglioma, bronchial carcinoid tumour
Various medical/surgical conditions	Trauma, carotid dissection, vertebral artery dissection, unruptured cerebral aneurysm, head and neck surgery, endovascular surgery, meningitis, haemolysis, low platelets, elevated liver enzymes, hypercalcaemia, phenytoin intoxication, porphyria
Blood products/immunosuppressant	Blood transfusions, erythropoietin, intravenous immunoglobulin, cyclophosphamide, interferon alpha, tacrolimus
Autoimmune pathologies	Thrombotic thrombocytopenic purpura, antiphospholipid antibody syndrome

haemorrhagic complication with RCVS is subarachnoid haemorrhage, most frequently localised in superficial cerebral sulci near the cerebral convexities.^{7 11}

Current recommended treatments for RCVS are the relief of symptoms with analgesics, blood pressure control in case of arterial hypertension, seizure prevention if needed and withdrawal and avoidance of any potential exogenous triggers, such as vasoactive medications or recreational drugs.^{7 9 13}

Drugs, including nimodipine, verapamil and magnesium sulfate, have been used to reduce arterial vasospasm with reduction of the intensity and number of headaches. However, prospective and retrospective studies suggest that these drugs do not affect the time-course of cerebral vasoconstriction and, therefore, the scientific evidence supporting their use is weak.^{4 7 11}

Differential diagnosis of RCVS and PRES is sometimes difficult, as the clinical and radiological features of these two syndromes overlap significantly. Moreover, the two entities share common risk factors, such as pre-eclampsia, and are frequently encountered concurrently. PRES-like reversible cerebral oedema is encountered in 9%–38% of patients with RCVS, while most patients with PRES (85%) demonstrate some element of RCVS-like cerebral vasoconstriction when conventional angiography is performed.⁸ When PRES-like features are encountered in cases of RCVS, the anatomic distribution of cerebral oedema is similar to PRES encountered in other settings. In addition, both PRES and RCVS share similar clinical features, including an acute, self-limited course and symptomatology, such as headache, confusion and seizure, as well as transient or, more rarely, permanent neurological deficits.²

RCVS is typically self-limiting. ‘Thunderclap headache’ or persistent headache can reoccur after the initial episode, but symptoms usually resolve within 3 weeks with no relapse after 1 month. Complete normalisation of cerebral vasospasm occurs within 12 weeks.³ Most patients affected by RCVS have a very good prognosis.^{4 9 11} Unfortunately, a small group of patients with RCVS, following the development of an ischaemic infarct, present delayed clinical worsening within the first few weeks after the appearance of the syndrome. Severe, permanent disability or death are reported in 5%–10% of patients affected by RCVS.^{9 14}

In the case reported here, the headache disappeared completely a few hours after surgery and did not reoccur. Two weeks after discharge, neurovascular ultrasound was normal and the neurologist decided that a control CT angiography was not needed. We recognise, however, that considering the mild degree of spasm the latter should have been preferred to prove full reversibility of the spasm.

The postpartum period deserves special attention since RCVS in this period is more likely to be associated with intracranial haemorrhage, vasogenic oedema, multifocal infarct and death.⁹ In a small retrospective study of 18 patients with postpartum angiopathy, Fugate *et al* describe neurological deficit in 50% of the patients, visual disturbances in 44%, encephalopathy in 33%, seizure in 28%, intracranial haemorrhage in 39%, vasogenic oedema and infarction in 35%. In addition, less than 50% recovered completely; the rest of the patients had permanent neurological deficits or died.¹⁵

Patients with a history of RCVS must be carefully advised to strictly avoid the use of potential triggers, some of which are commonly encountered in over-the-counter medicines (see table 1). In obstetric patients presenting with acute RCVS or with a history of RCVS, it is recommended to avoid all potential

exogenous triggers (see table 1) and, in particular, vasoactive medications. This might be particularly challenging for planned caesarean section under regional anaesthesia, as the use of phenylephrine has become standard practice to prevent and treat arterial hypotension. There is, however, no clear benefit of using ephedrine or norepinephrine as an alternative, as they are also suspected to trigger RCVS.² Optimal control of blood pressure during pregnancy and delivery must also include the control and treatment of arterial hypertension. The use of vasodilators, such as calcium channel blockers, has been proposed to treat or prevent vasospasm in RCVS; however, there is no evidence that these vasodilators influence patient outcome.⁸

In summary, the occurrence of a ‘thunderclap headache’ represents a ‘red flag’ and requires cerebral angiographic imaging even if the symptom disappears. Even though phenylephrine is currently administered routinely to prevent or treat arterial hypotension during caesarean section under spinal anaesthesia, clinicians should be aware that it may rarely trigger RCVS. In addition, parturients presenting with an acute episode or a history of RCVS will require careful coordinated management by a multidisciplinary team involving neurologists, obstetricians, anaesthesiologists and pharmacologists.

Learning points

- ▶ ‘Thunderclap headache’ requires cerebral angiographic imaging, even if the symptom disappears.
- ▶ Reversible cerebral vasoconstriction syndrome (RCVS) can be precipitated by several triggers, including phenylephrine or ephedrine, which are often used during the peripartum and postpartum periods.
- ▶ Pregnancy and the postpartum period are conditions associated with RCVS.
- ▶ RCVS in the postpartum period is often more severe than at other times and deserves special attention.
- ▶ Coordinated multidisciplinary management in known cases of RCVS involving neurologists, obstetricians, pharmacists and anaesthesiologists is essential.

Contributors SLS wrote the initial draft of the article and contributed to the revisions. CB and GS contributed to the initial conception and writing of the article and made several revisions of the paper. All authors approved the final manuscript for publication.

Funding The authors have not declared a specific grant for this research from any funding agency in the public, commercial or not-for-profit sectors.

Competing interests None declared.

Patient consent for publication Obtained.

Provenance and peer review Not commissioned; externally peer reviewed.

ORCID iD

Georges Savoldelli <http://orcid.org/0000-0002-8968-6920>

REFERENCES

- 1 Geocadin RG, Razumovsky AY, Wityk RJ, *et al*. Intracerebral hemorrhage and postpartum cerebral vasculopathy. *J Neurol Sci* 2002;205:29–34.
- 2 Miller TR, Shivashankar R, Mossa-Basha M, *et al*. Reversible cerebral vasoconstriction syndrome, part 1: epidemiology, pathogenesis, and clinical course. *AJNR Am J Neuroradiol* 2015;36:1392–9.
- 3 Ducros A, Wolff V. The typical thunderclap headache of reversible cerebral vasoconstriction syndrome and its various triggers. *Headache* 2016;56:657–73.
- 4 Singhal AB, Hajji-Ali RA, Topcuoglu MA, *et al*. Reversible cerebral vasoconstriction syndromes: analysis of 139 cases. *Arch Neurol* 2011;68:1005–12.
- 5 Kirton A, Diggle J, Hu W, *et al*. A pediatric case of reversible segmental cerebral vasoconstriction. *Can. j. neurol. sci.* 2006;33:250–3.
- 6 Chen S-P, Fuh J-L, Wang S-J, *et al*. Magnetic resonance angiography in reversible cerebral vasoconstriction syndromes. *Ann Neurol* 2010;67:648–56.

- 7 Ducros A, Boukobza M, Porcher R, *et al.* The clinical and radiological spectrum of reversible cerebral vasoconstriction syndrome. A prospective series of 67 patients. *Brain* 2007;130:3091–101.
- 8 Ducros A. Reversible cerebral vasoconstriction syndrome. *Lancet Neurol* 2012;11:906–17.
- 9 Calabrese LH, Dodick DW, Schwedt TJ, *et al.* Narrative review: reversible cerebral vasoconstriction syndromes. *Ann Intern Med* 2007;146:34–44.
- 10 Dodick DW, Brown RD, Britton JW, *et al.* Nonaneurysmal thunderclap headache with diffuse, multifocal, segmental, and reversible vasospasm. *Cephalalgia* 1999;19:118–23.
- 11 Ducros A, Fiedler U, Porcher R, *et al.* Hemorrhagic manifestations of reversible cerebral vasoconstriction syndrome: frequency, features, and risk factors. *Stroke* 2010;41:2505–11.
- 12 Santos E, Zhang Y, Wilkins A, *et al.* Reversible cerebral vasoconstriction syndrome presenting with haemorrhage. *J Neurol Sci* 2009;276:189–92.
- 13 Wolff V, Lauer V, Rouyer O, *et al.* Cannabis use, ischemic stroke, and multifocal intracranial vasoconstriction: a prospective study in 48 consecutive young patients. *Stroke* 2011;42:1778–80.
- 14 Singhal AB. Postpartum angiopathy with reversible posterior leukoencephalopathy. *Arch Neurol* 2004;61:411–6.
- 15 Fugate JE, Ameriso SF, Ortiz G, *et al.* Variable presentations of postpartum angiopathy. *Stroke* 2012;43:670–6.

Copyright 2019 BMJ Publishing Group. All rights reserved. For permission to reuse any of this content visit <https://www.bmj.com/company/products-services/rights-and-licensing/permissions/>
BMJ Case Report Fellows may re-use this article for personal use and teaching without any further permission.

Become a Fellow of BMJ Case Reports today and you can:

- ▶ Submit as many cases as you like
- ▶ Enjoy fast sympathetic peer review and rapid publication of accepted articles
- ▶ Access all the published articles
- ▶ Re-use any of the published material for personal use and teaching without further permission

Customer Service

If you have any further queries about your subscription, please contact our customer services team on +44 (0) 207111 1105 or via email at support@bmj.com.

Visit casereports.bmj.com for more articles like this and to become a Fellow