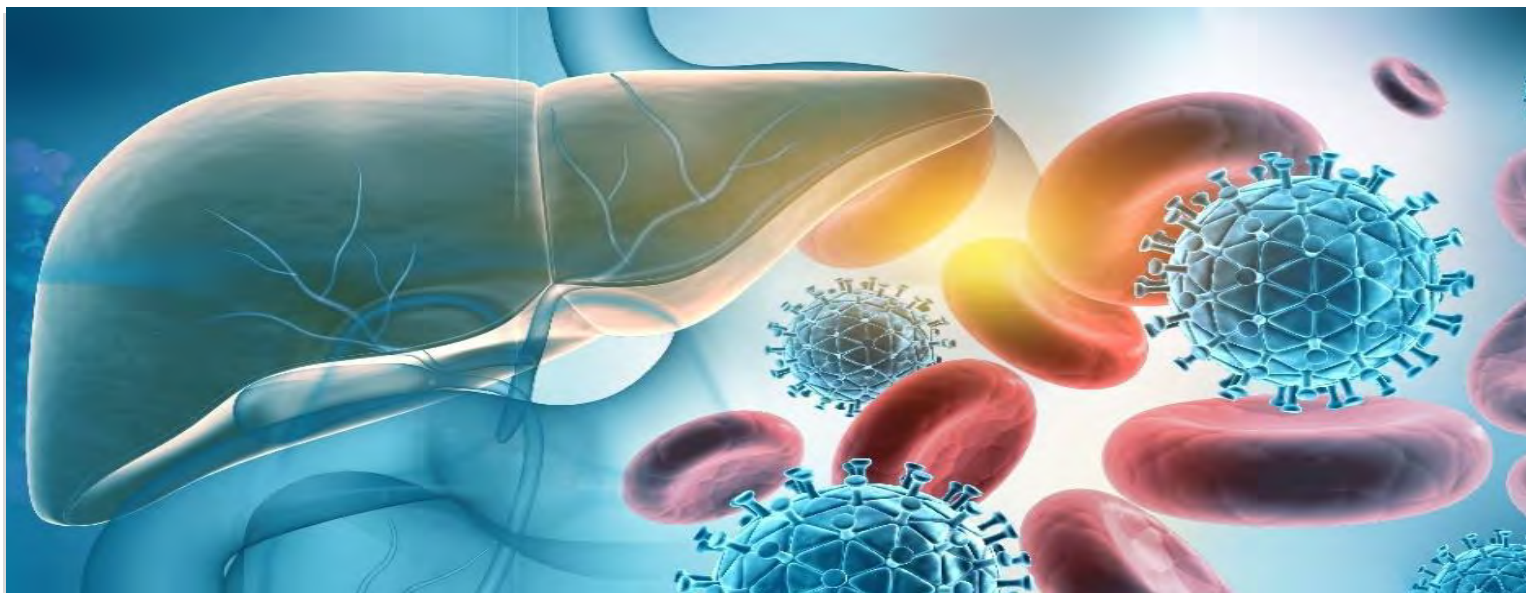


Hôpital du Valais
Spital Wallis

Symposium Hépato-biliaire & Médecine interne générale



Surgical Management

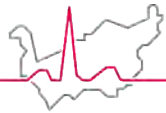
Dr Méd. Fournier Ian

Spécialiste chirurgie générale, spéc. chirurgie viscérale membre FMH

Médecin adjoint service de chirurgie générale de l'HVS

Médecin consultant service de chirurgie viscérale et transplantation des
HUG

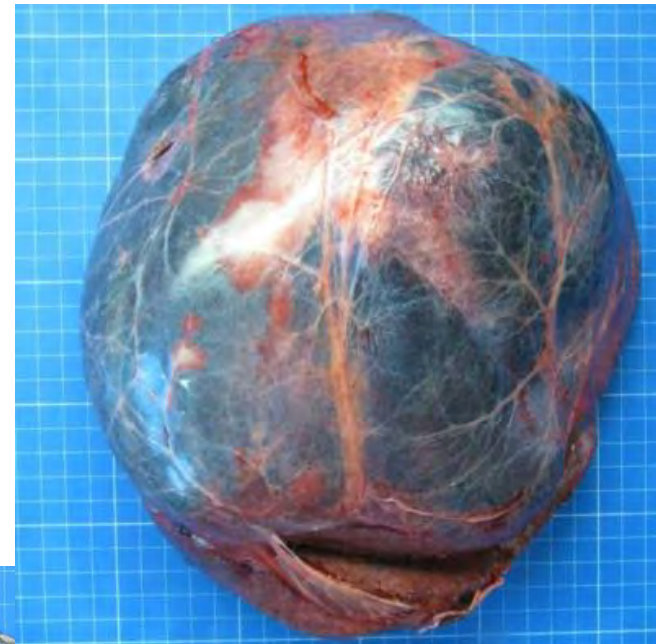Chargé d'enseignement à la faculté de Médecine Humaine UNIGE

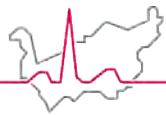


Hôpital du Valais
Spital Wallis

Introduction

- **Historical Mile Stones**
- **Indication**
 - Mainly Oncological
 - Benin lesion with local complication
- **Resectability**
 - Anatomy limits
 - Functional limits
- **Minimally invasive liver surgery**
- **MHS**





Historical mile stones in liver surgery

Ancient/Antic Liver Surgery limited to infectious condition

- **Ancient Egypt:**

- Medical texts, such as the Ebers Papyrus (circa 1550 BCE), mention procedures for draining abscesses in different parts of the body.

- **Ancient Greece and Rome:**

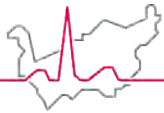
- Hippocrates and Galen, described surgical procedures for abscess drainage and wound care. However, specific reports of liver abscess drainage are rare.

- **Medieval and Islamic Medicine:**

- During the medieval period, Islamic scholars like Al-Razi (Rhazes) and Avicenna (Ibn Sina) made contributions to surgical techniques. Their works discussed abscess drainage methods but provided limited details about liver abscesses specifically.



Historical development in liver surgery



Hôpital du Valais
Spital Wallis

19th Century

1. Emerging anesthesia permitted further deployment
 2. Limitation in asepsia, liver function and anatomy knowledge
- **Johann Nepomuk von Ritter (Austria, 1782–1856):** performing one of the earliest documented hepatic surgeries in 1816. He attempted to ligate the hepatic artery to control bleeding in a patient with hepatic injury.

20th Century

- Dr. Evarts Graham (USA): In 1933, the earliest successful liver tumor resections.
- The 1950s saw significant advancements in anesthesia, allowing for longer and more complex surgical procedures. Improved perioperative care further reduced the risk of complications.
 - Dr. Thomas E. Starzl (USA): Often referred to as the "father of transplantation," In 1967, he performed the first successful liver transplant, paving the way for organ transplantation as a viable treatment option for end-stage liver disease.
 - Dr. Henri Bismuth (France): anatomical liver resection emphasized preserving functional liver segments.

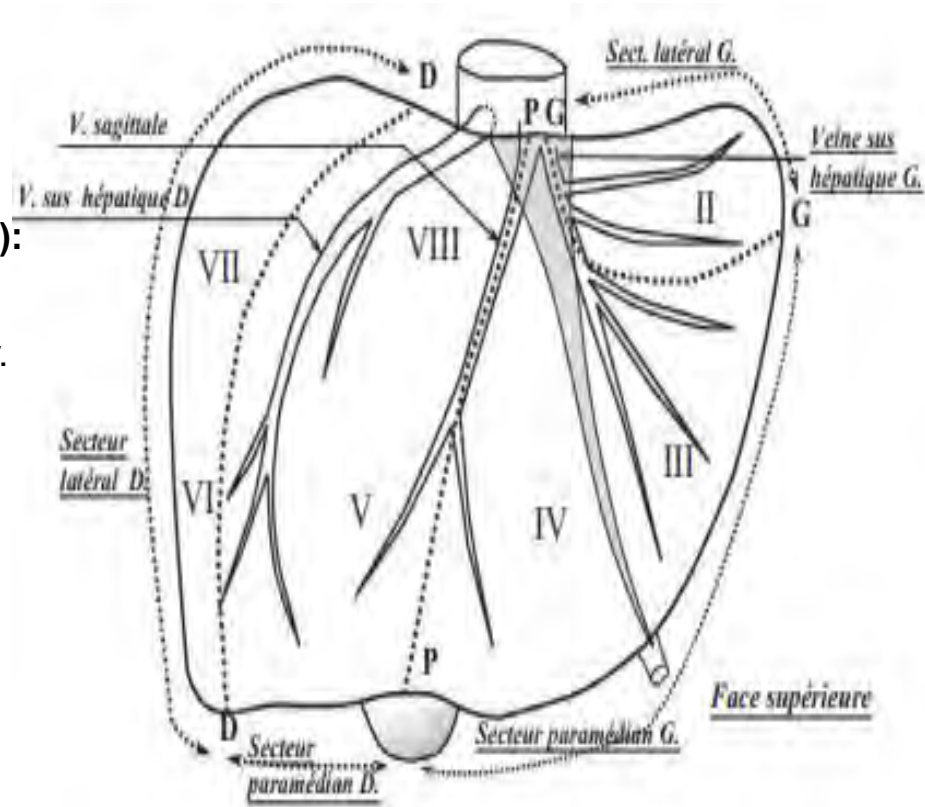
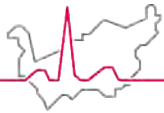
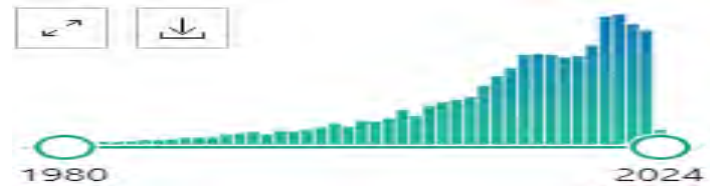

Figure 2 Liver segments described by Couinaud. Adapted from *La Presse Médicale*, 1954¹

Oncological Indication

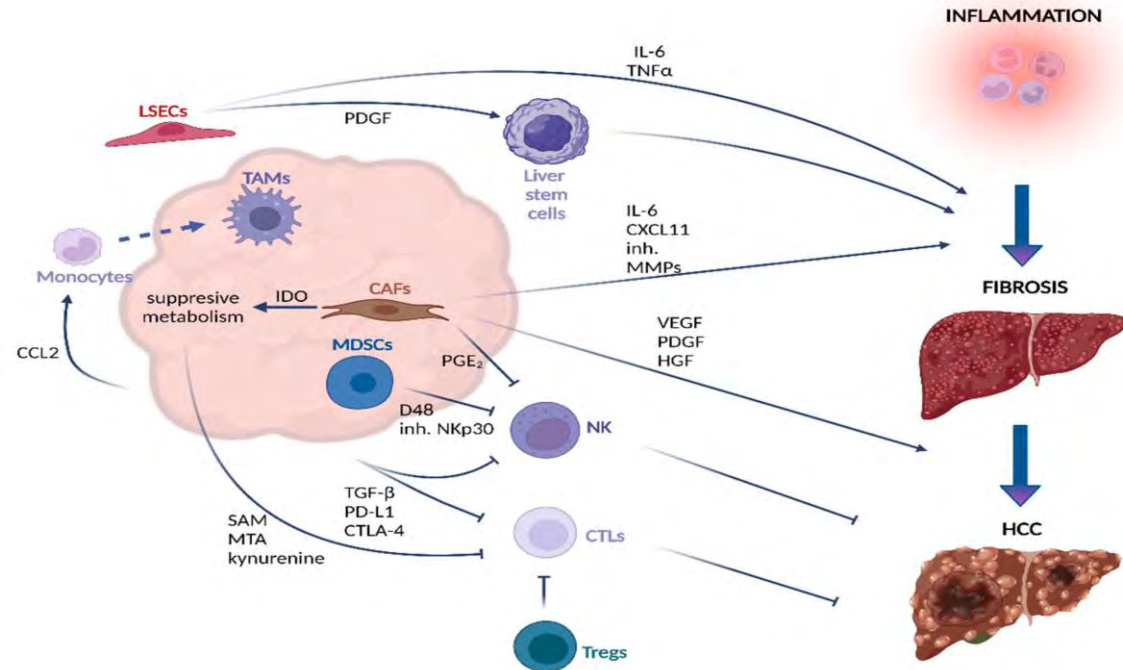


Hôpital du Valais
Spital Wallis



• Liver Primary

- HCC
(Hepatocarcinoma)
- ICCa (Intrahepatic
Cholangiocarcinoma)
- PCCa (Hilar
Cholangiocarcinoma)




Best Practice & Research Clinical
Gastroenterology

Volume 28, Issue 5, October 2014, Pages 881-896

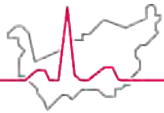


10

Liver resection for HCC: Patient's selection and controversial scenarios

François Cauchy M.D. (Fellow in Surgery)^{a, b}, Olivier Soubrane M.D. (Professor of Surgery)^{a, b},
Jacques Belghiti M.D. (Professor of Surgery)^{a, b} 

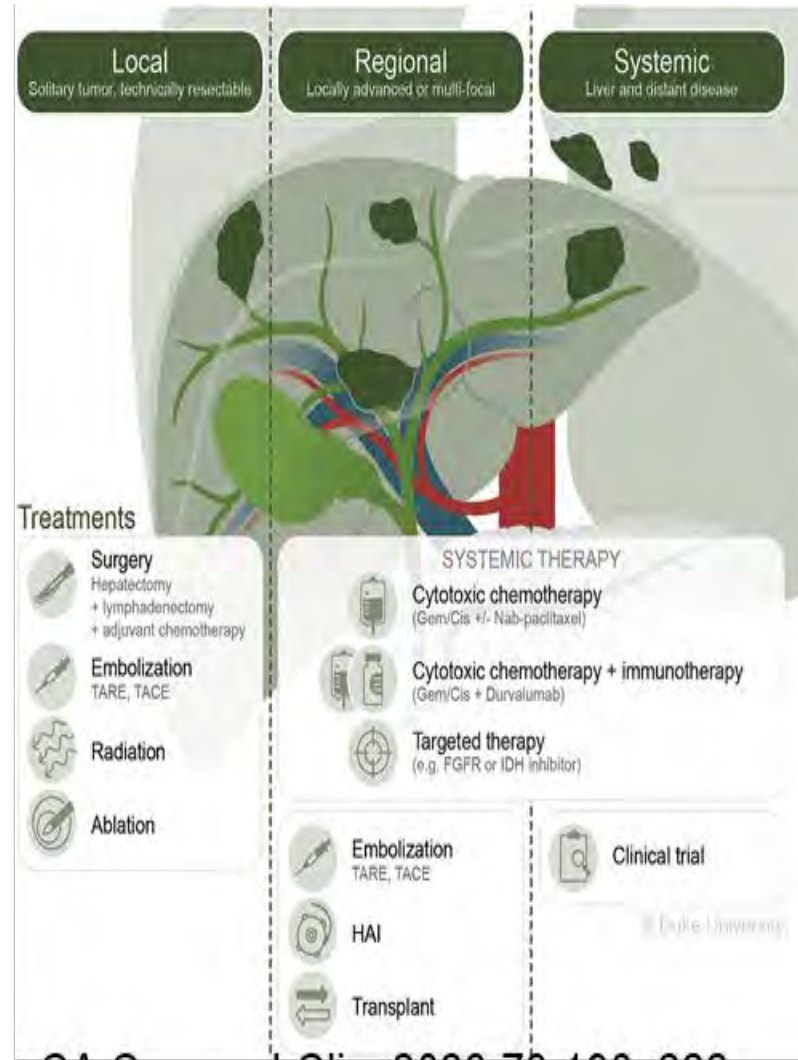
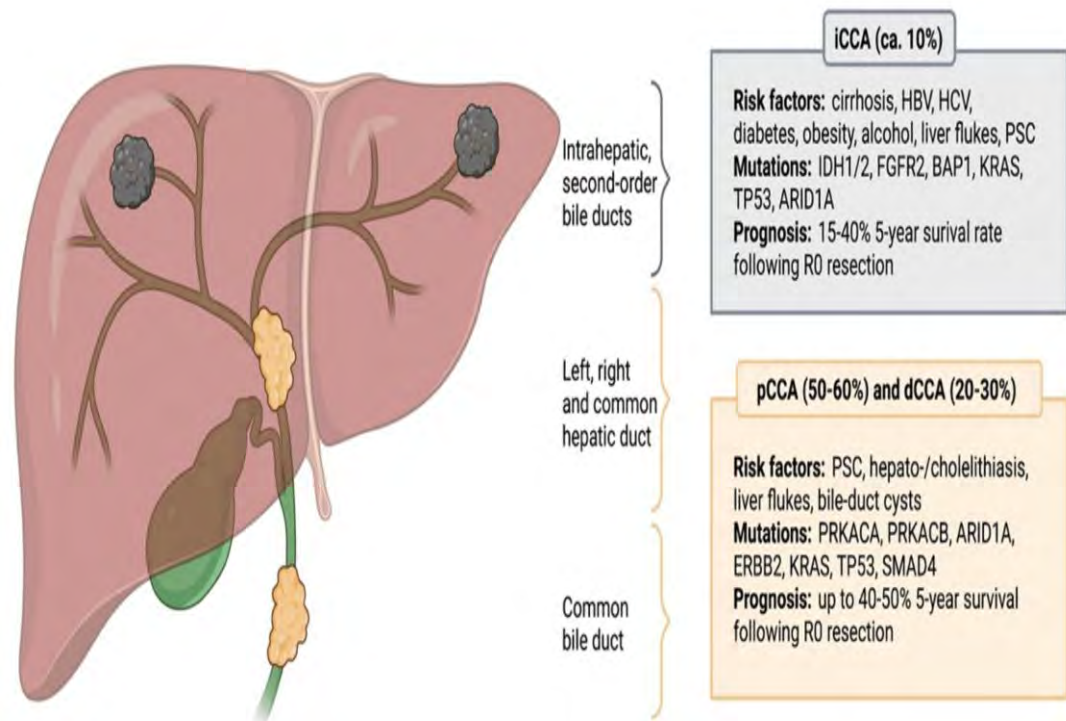
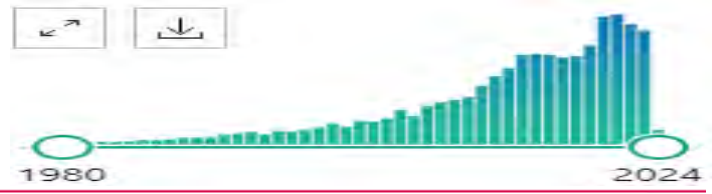Oncological Indication



Hôpital du Valais
Spital Wallis

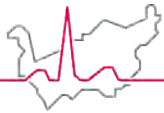
• Liver Primary

- HCC (Hepatocarcinoma)
- ICCa (Intrahepatic Cholangiocarcinoma)
- PCCa (Hilar cholangiocarcinoma)

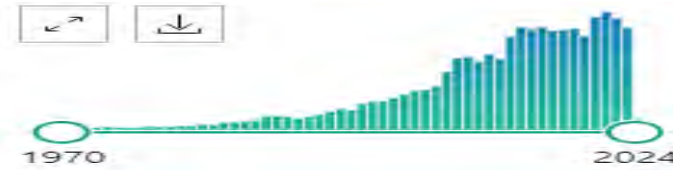

CA Cancer J Clin. 2023;73:198–222.

Oncological Indication



Hôpital du Valais
Spital Wallis



- **Liver Secondary**

- colorectal AdCa Met's
- NET Met's
- Other Met's
 - Upper GI AdCa
 - Brest AdCa
 - Ovaries Carcioma
 - Melanoma

ANNALS OF SURGERY
A Monthly Review of Surgical Science Since 1885

Clinical Score for Predicting Recurrence After Hepatic Resection for Metastatic Colorectal Cancer

Analysis of 1001 Consecutive Cases

[Yuman Fong, MD](#),[†] [Joseph Fortner, MD](#),[†] [Ruth L. Sun, BA](#),[†] [Murray F. Brennan, MD](#),[†] and [Leslie H. Blumgart, MD](#),
FRCS[†]



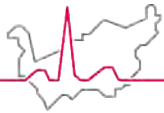
EDITORIAL

Liver resection for colorectal cancer liver metastases: An often-neglected opportunity for cure

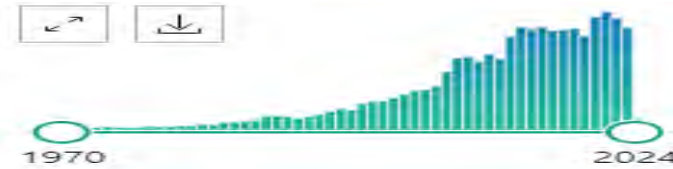Mustafa Raoof MD, Yuman Fong MD

First published: 24 September 2020 | <https://doi.org/10.1002/jso.26192>

Oncological Indication



Hôpital du Valais
Spital Wallis



- **Liver Secondary**

- colorectal AdCa Met's
- NET Met's
- Other Met's
 - Upper GI AdCa
 - Brest AdCa
 - Ovaries Carcioma
 - Melanoma

ANNALS OF SURGERY
A Monthly Review of Surgical Science Since 1885

Clinical Score for Predicting Recurrence After Hepatic Resection for Metastatic Colorectal Cancer

Analysis of 1001 Consecutive Cases






The American Journal of Surgery
Volume 226, Issue 5, November 2023, Pages 623-630



ngart, MD,

Review Article

Management of neuroendocrine tumor liver metastases ☆

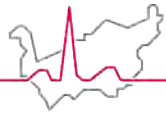
Alex Harrelson^{a,1}, Rongzhi Wang^{b,1}, Addison Stewart^a, Clark Ingram^a, Andrea Gillis^b,
J. Bart Rose^b, Bassel El-Rayes^c, Asfar Azmi^d, Herbert Chen^b   

EDITO.....

Liver resection for colorectal cancer liver metastases: An often-neglected opportunity for cure

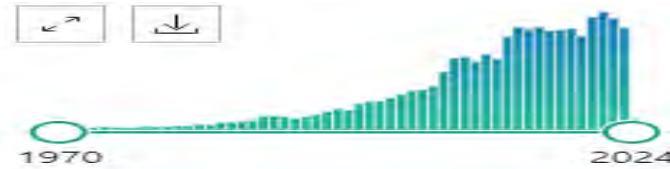Mustafa Raoof MD, Yuman Fong MD 

First published: 24 September 2020 | <https://doi.org/10.1002/jso.26192>



Hôpital du Valais
Spital Wallis

Oncological Indication



- **Liver Secondary**

- colorectal AdCa Met's
- NET Met's
- Other Met's
 - Upper GI AdCa
 - Brest AdCa
 - Ovaries Carcioma
 - Melanoma

ANNALS OF SURGERY

A Monthly Review of Surgical Science Since 1885

Clinical Score for Predicting Recurrence After Hepatic Resection for Metastatic Colorectal Cancer

Analysis of 1001 Consecutive Cases



The American Journal of Surgery

Volume 226, Issue 5, November 2023, Pages 623-630



ngart, MD,

Review Article

Management of neuroendocrine tumor liver



Original Clinical Science

Hepatectomy for Liver Metastasis of Gastric Cancer: A Meta-Analysis

Jun-Kai Cui, MM^{1*}, Mei Liu, MD^{2*}, and Xiao-Ke Shang, MD³

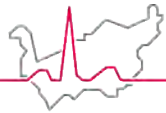
Surgical Innovation
2019, Vol. 26(6) 692-697
© The Author(s) 2019
Article reuse guidelines:
sagepub.com/journals-permissions
DOI: 10.1177/1553350619856491
journals.sagepub.com/home/sri

^{1, a}, Andrea Gillis ^b,

ver metastases: An

so.26192

Oncological Indication



Hôpital du Valais
Spital Wallis



• Liver Secondary

- colorectal AdCa Met's
- NET Met's
- Other Met's
 - Upper GI AdCa
 - Brest AdCa
 - Ovaries Carcioma
 - Melanoma

ANNALS OF SURGERY

A Monthly Review of Surgical Science Since 1885

Clinical Score for Predicting Recurrence After Hepatic Resection for Metastatic Colorectal Cancer

Analysis of 1001 Consecutive Cases



The American Journal of Surgery
Volume 226, Issue 5, November 2023, Pages 623-630



ngart, MD,



Surgical Oncology Clinics of North America
Volume 30, Issue 1, January 2021, Pages 27-37



er

Surgical Management of Breast Cancer Liver Metastasis

Original Clinical Science

Hepatectomy for Liver Gastric Cancer: A Meta-Analysis

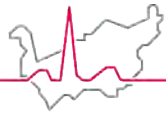
Amir A. Rahnemai-Azar MD^a, Luke V. Selby MD, MS^b, Maryam B. Lustberg MD, MPH^c,
Timothy M. Pawlik MD, MPH, PhD^b

ases: An

journals.sagepub.com/home/sri
SAGE

Jun-Kai Cui, MM^{1*}, Mei Liu, MD^{2*}, and Xiao-Ke Shang, MD³

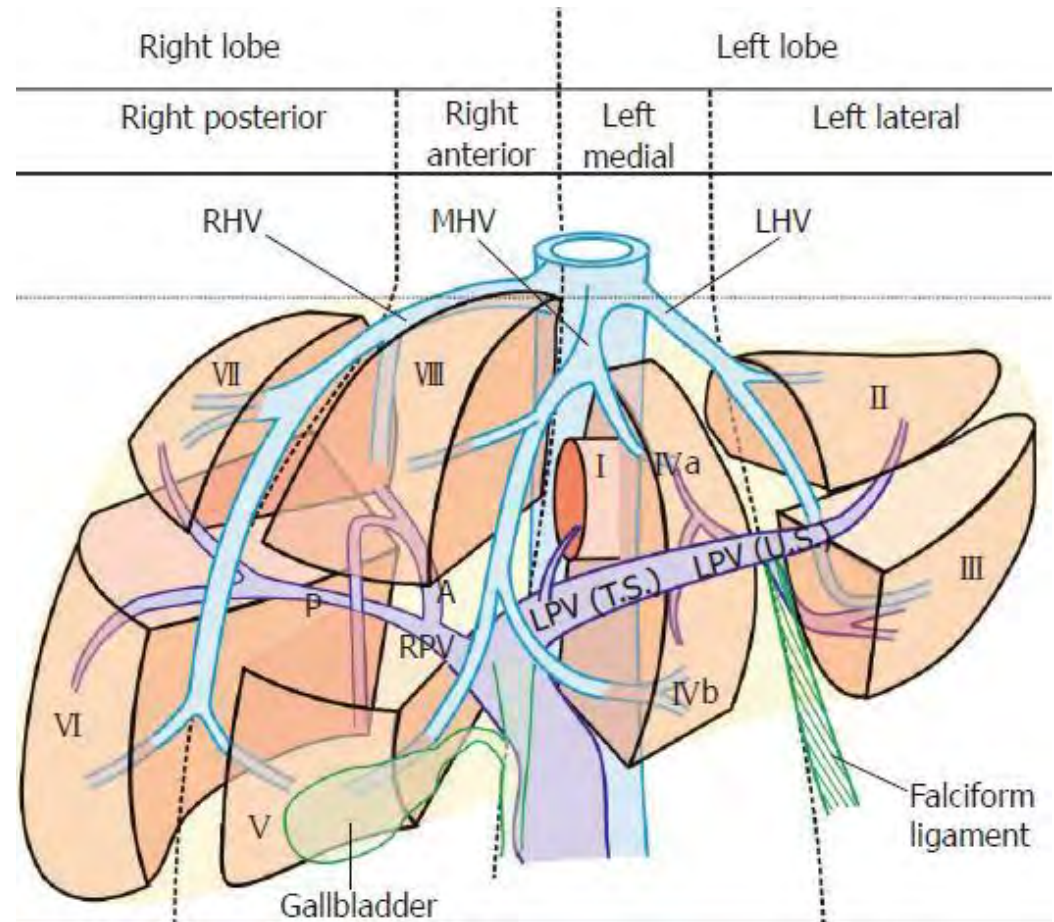
so.26192

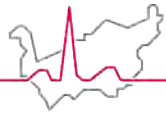


Surgery Strategy & Liver Geography

- **Resectability**

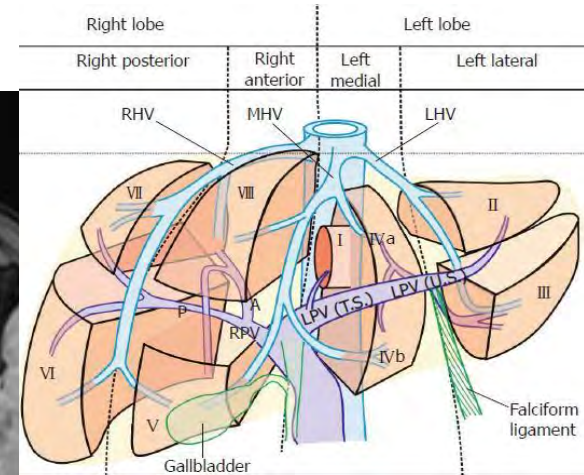
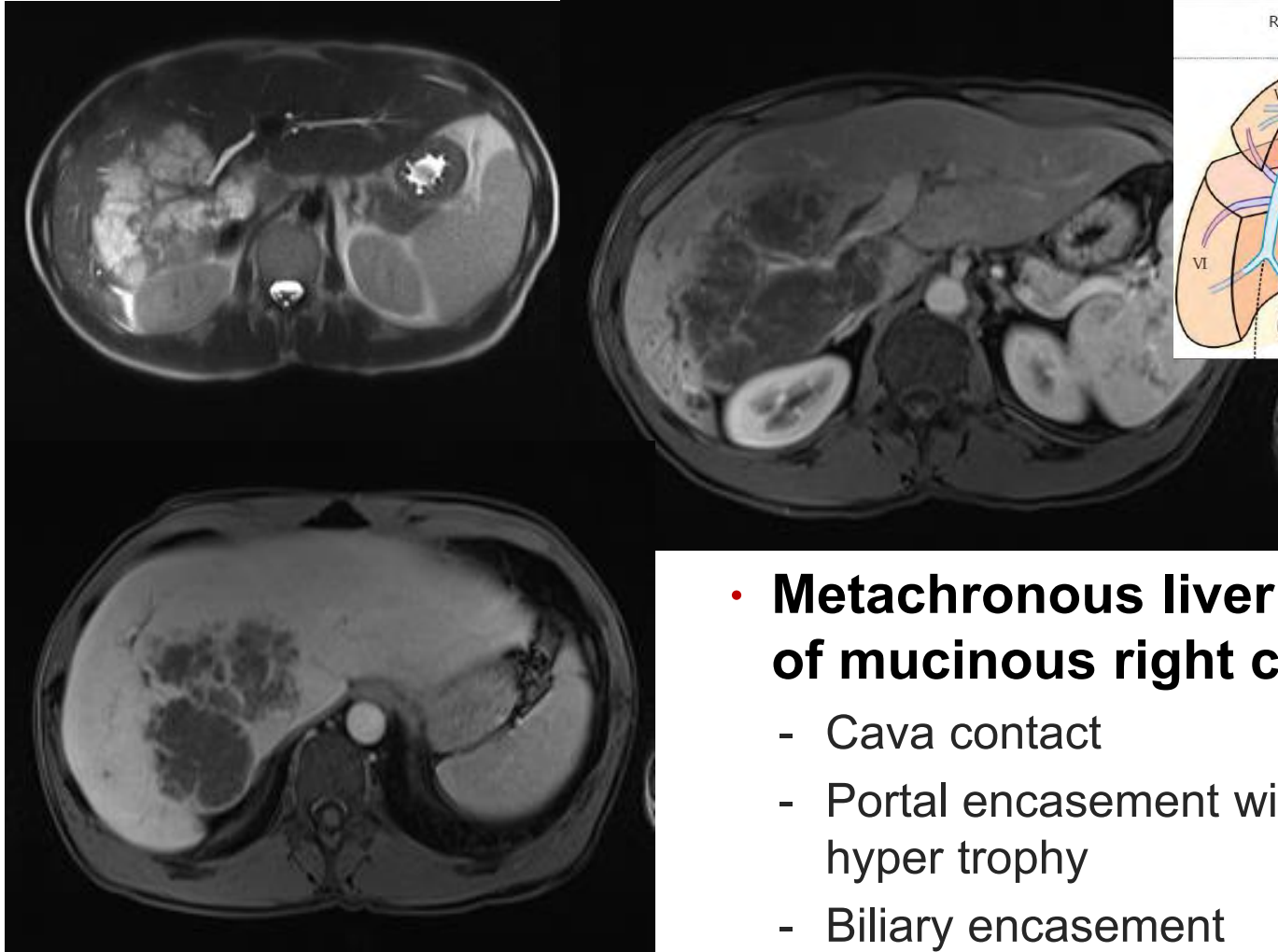
- New burden with increasing complexity of reconstruction possibility
- Inflow supply (portal and arterial)
- Outflow supra hepatic vein
- Bile production
- Liver function
- Size
- Underlying hepatic disease (cirrhosis/SOs)



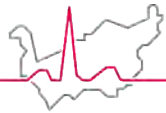


Hôpital du Valais
Spital Wallis

Surgery Strategy & Liver Geography

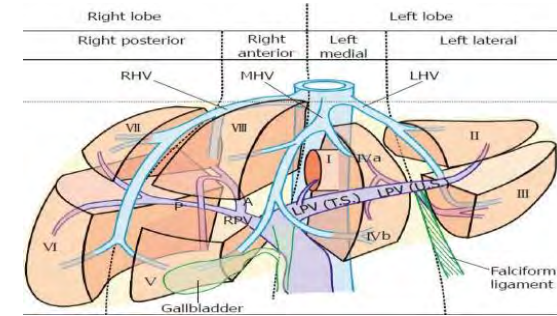
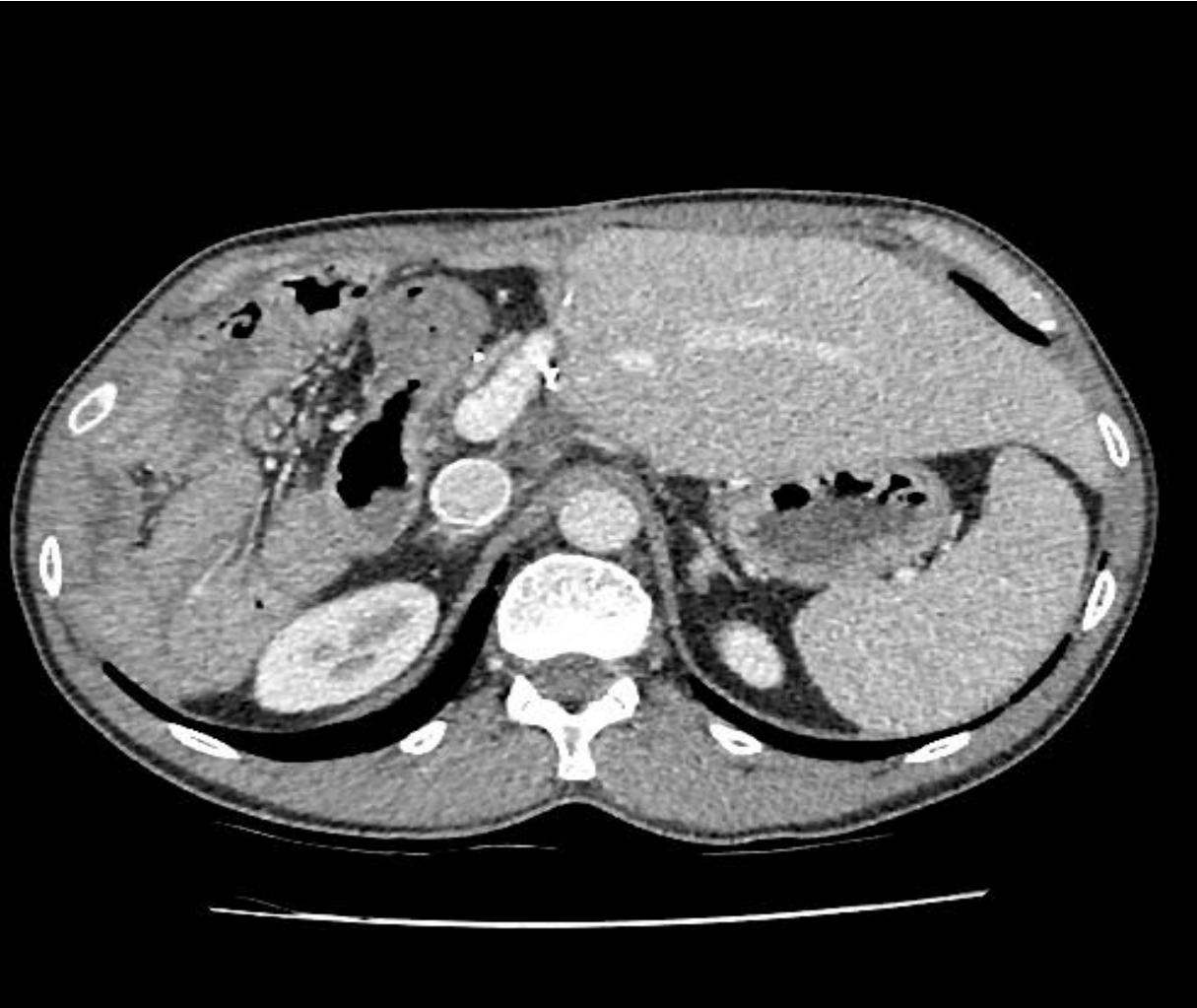

- **Metachronous liver metastasis of mucinous right colon cancer**
 - Cava contact
 - Portal encasement with compensatory hyper trophy
 - Biliary encasement



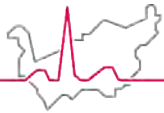
Hôpital du Valais
Spital Wallis

Surgery Strategy & Liver Geography



- **Right Extended hepatectomy**

- Portal jumping venous graft
- Biliodigestive hepatico jejunostomy
- Protetical cava graft replacement



Hôpital du Valais
Spital Wallis

Surgery Strategy & Liver Geography

- **Resectability:**

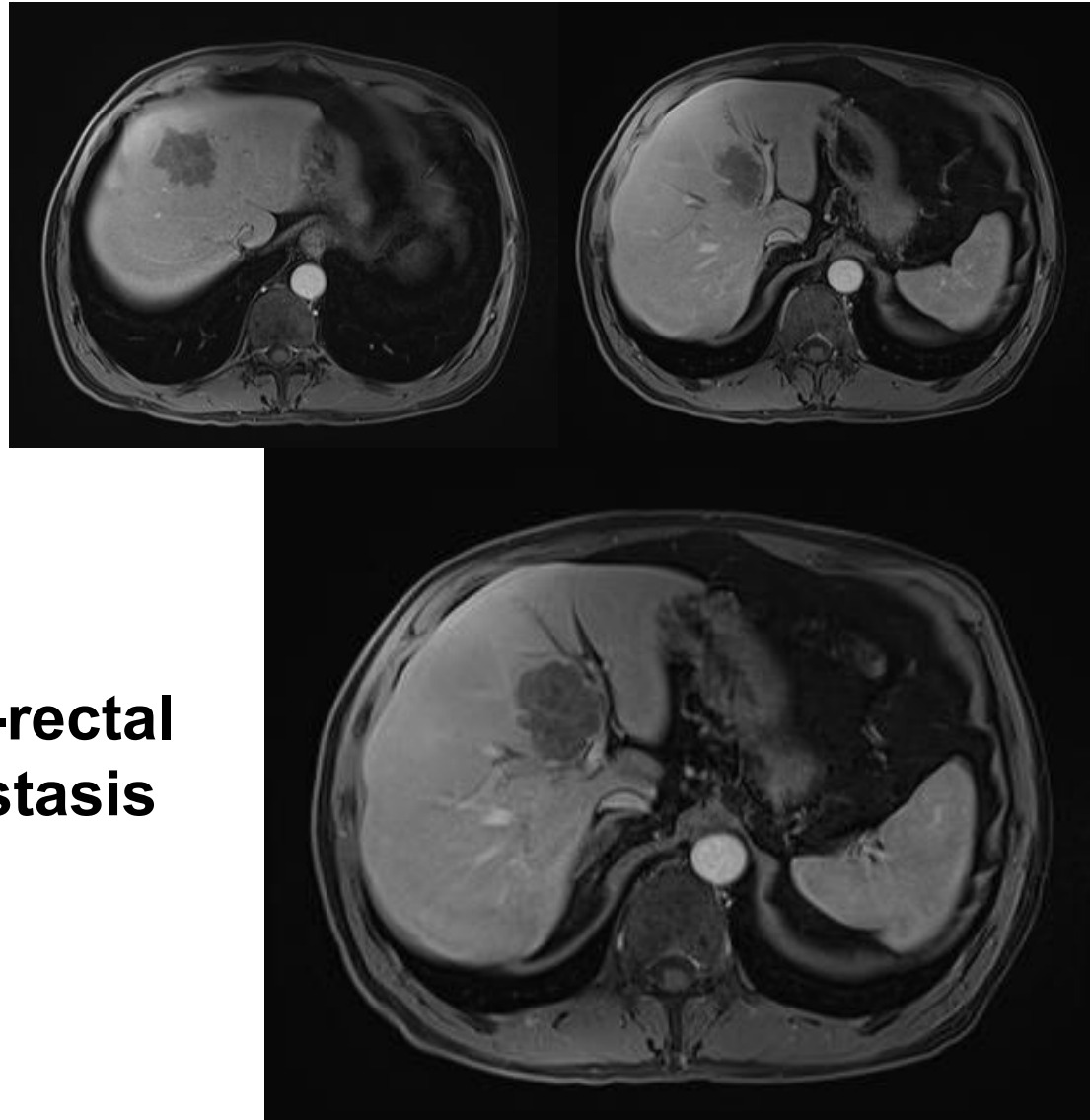
- Anatomy

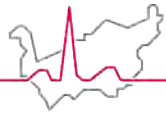
Chemotherapy
downsizing for margin and
anatomy sparing resection

Independent predictor
for local recurrence

- **Synchronous liver low-rectal
adenocarcinoma metastasis**

- Seg IV/V/VIII





Hôpital du Valais
Spital Wallis

Surgery Strategy & Liver Geography

ANNALS OF SURGERY
A Monthly Review of Surgical Science Since 1885

Ann Surg. 1996 Oct; 224(4): 509–522.

doi: [10.1097/00000658-199610000-00009](https://doi.org/10.1097/00000658-199610000-00009)

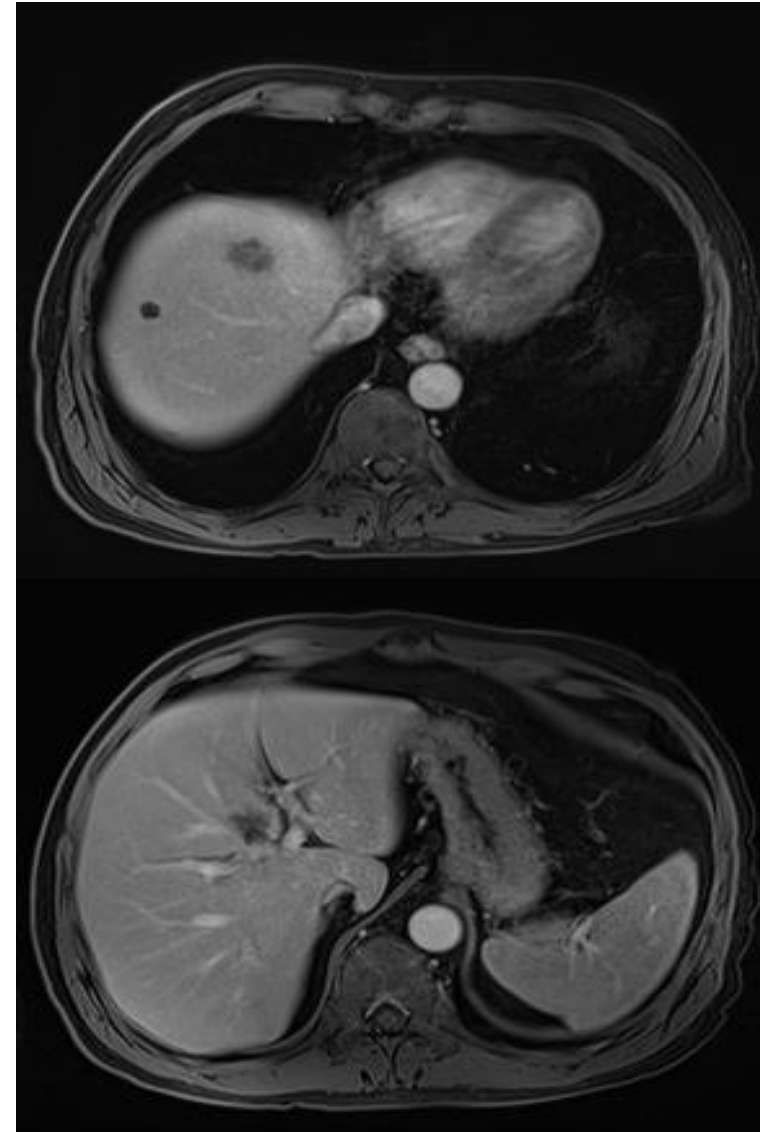
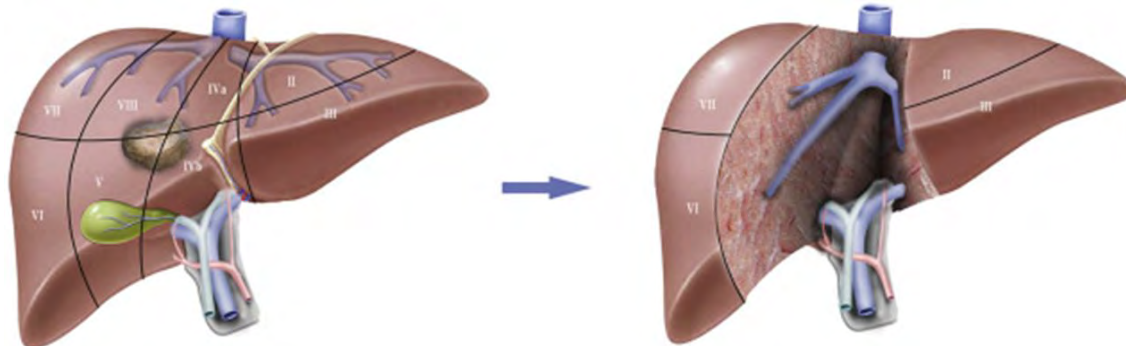
PMCID: PMC1235414

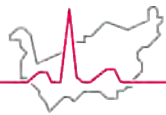
PMID: [8857855](https://pubmed.ncbi.nlm.nih.gov/8857855/)

Resection of nonresectable liver metastases from colorectal cancer after neoadjuvant chemotherapy.

[H Bismuth](#), [R Adam](#), [F Lévi](#), [C Farabos](#), [F Waechter](#), [D Castaing](#), [P Majno](#), and [L Engerran](#)

- **S/p 6 cure of FOLFOXlri + Bevacizumab**





Dealing with remnant Liver

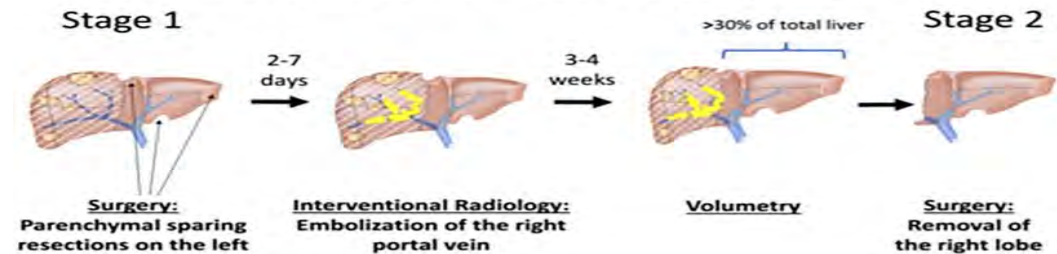
Hôpital du Valais
Spital Wallis

- **Indication**

- **Resectability**

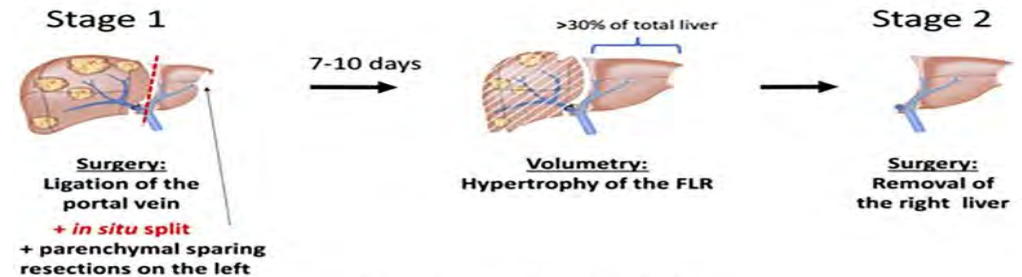
- Liver function
- Size
- Underlying disease
- Major resection with compensatory growth
- Parenchymal sparing / cherry picking / Swiss cheese procedure

Portal Vein embolization (PVE)



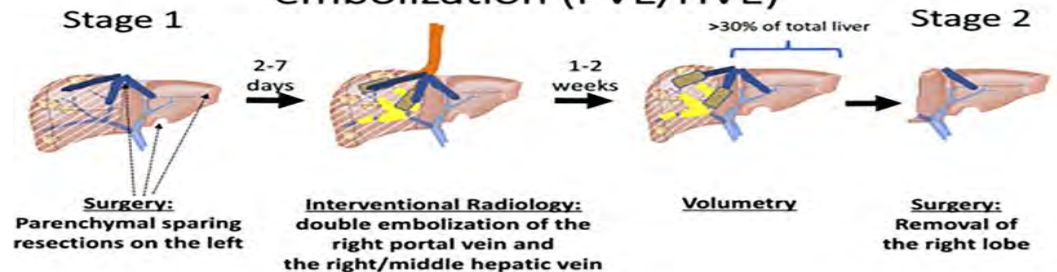Brouquet et al. J Clin Oncol 2011

In-situ-split/ALPPS

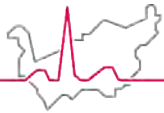


Schnitzbauer et al. Ann Surg 2012

Simultaneous portal and hepatic vein embolization (PVE/HVE)



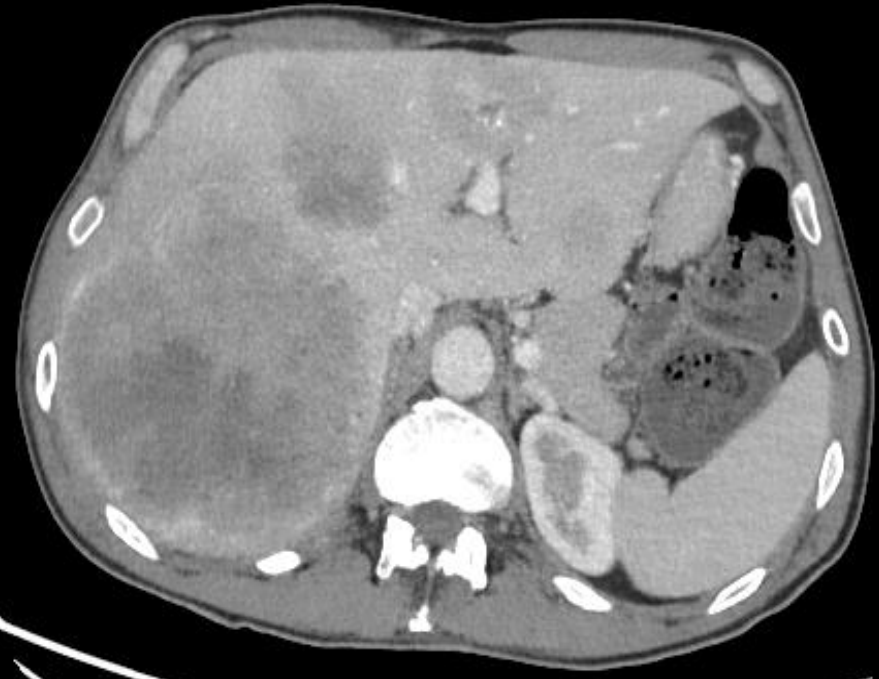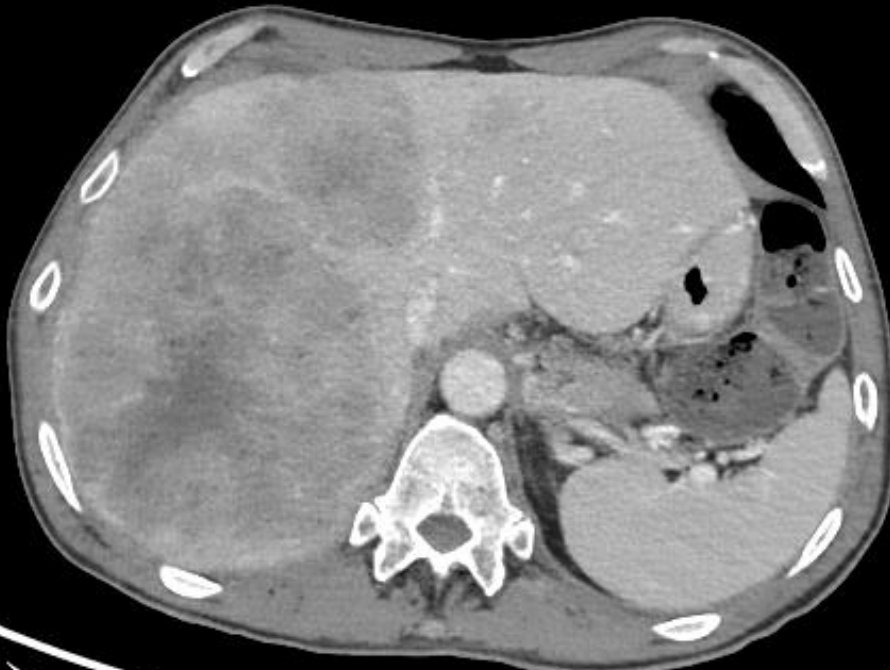Heil/Schadde et al. BJS 2021



2 Step & PVE dealing with remnant liver

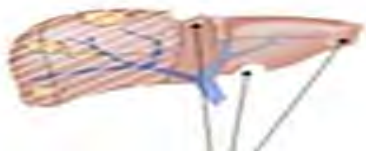Hôpital du Valais
Spital Wallis

- **Synchronous low rectal adenocarcinoma liver metastasis**

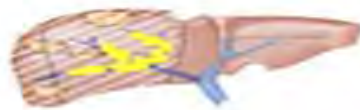


Portal Vein embolization (PVE)

Stage 1



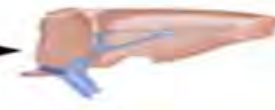2-7
days

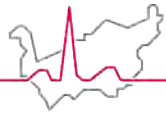


3-4
weeks



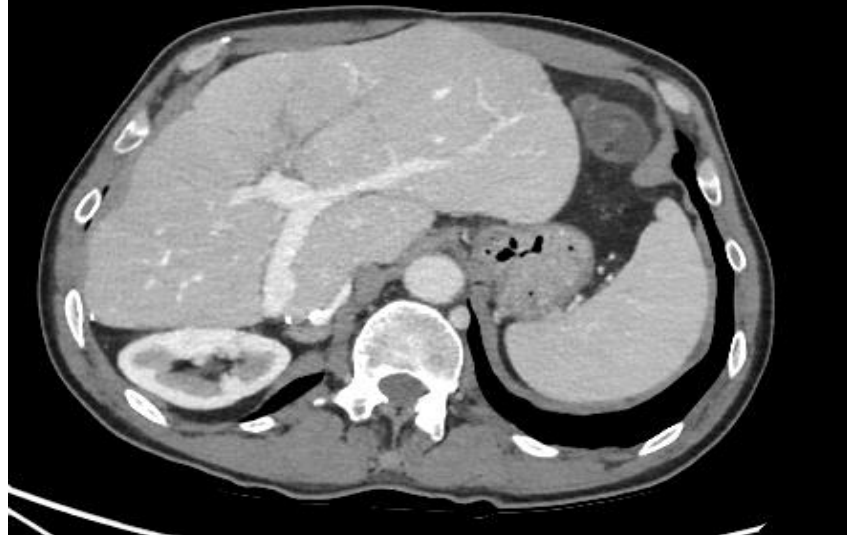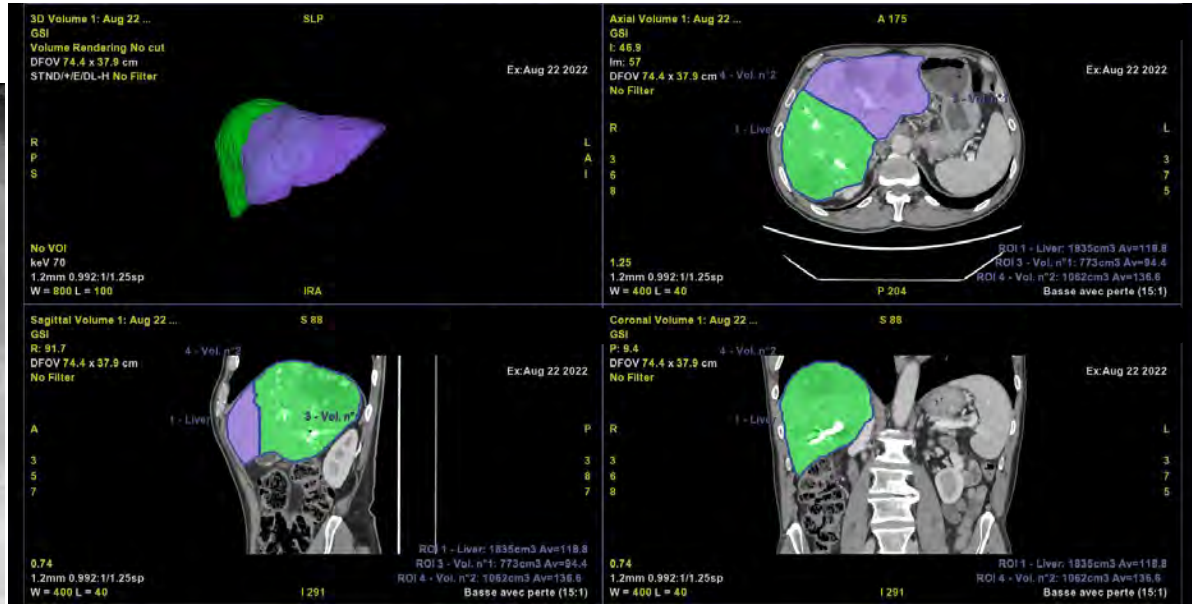
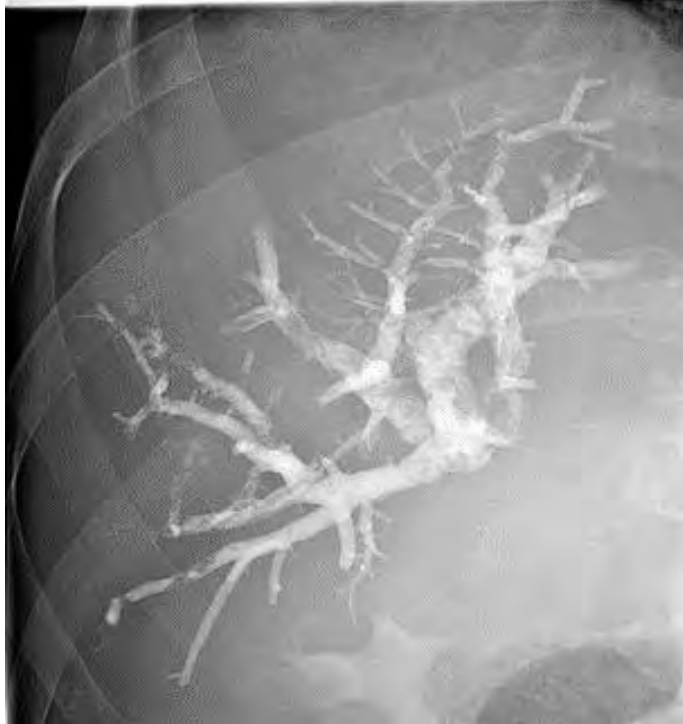Stage 2



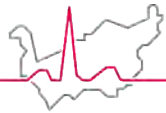


Hôpital du Valais
Spital Wallis

2 Step & PVE dealing with remnant liver



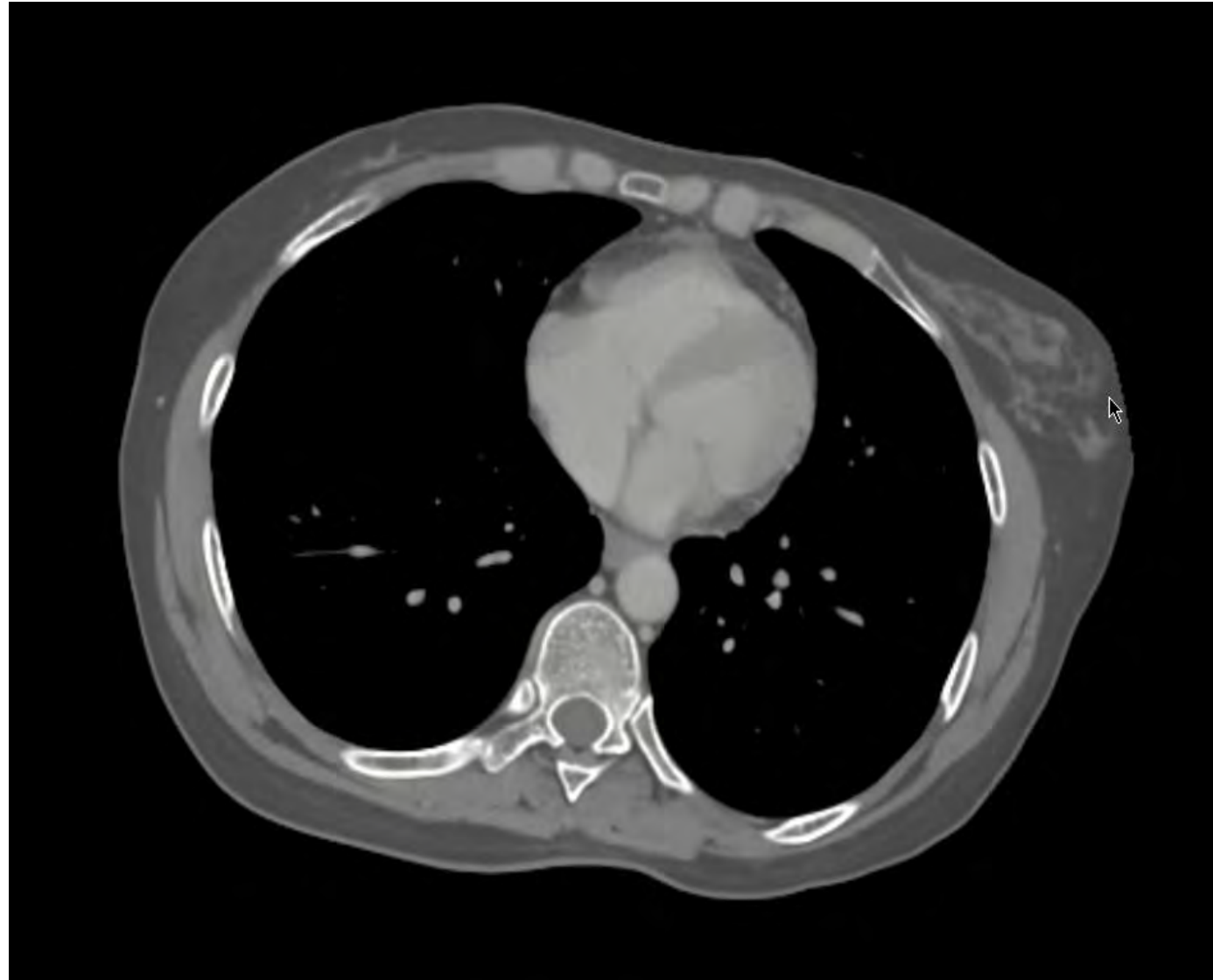- **Diagnose in 21st December 2021**
- **Liver end treatment 9 September 2022**
- **Rectum end treatment 22 October 2022**
- **End adjuvant chemotherapy January 2023**

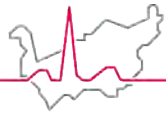


Cherry Picking / Swiss Cheese

Hôpital du Valais
Spital Wallis

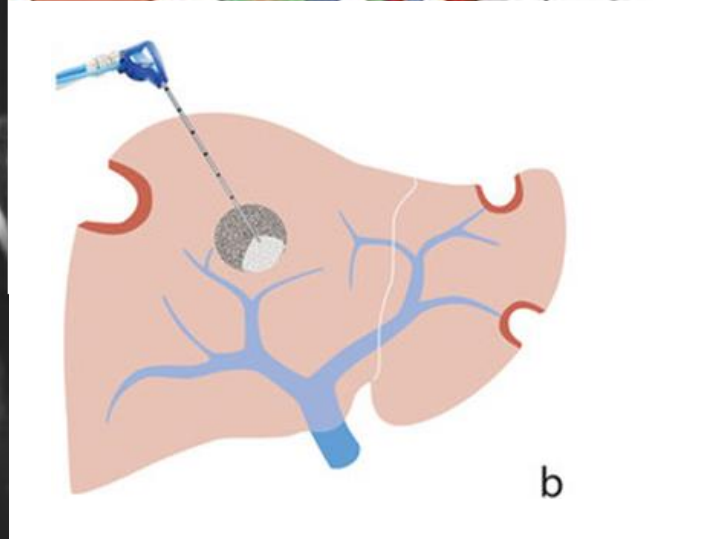
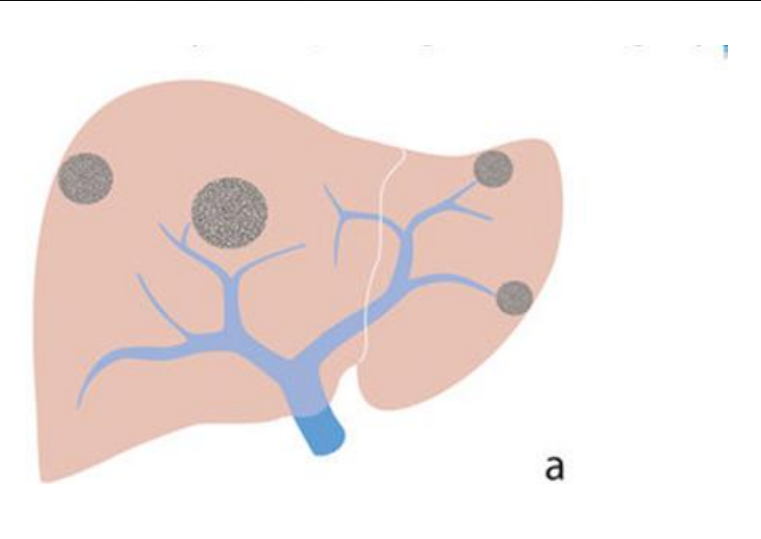
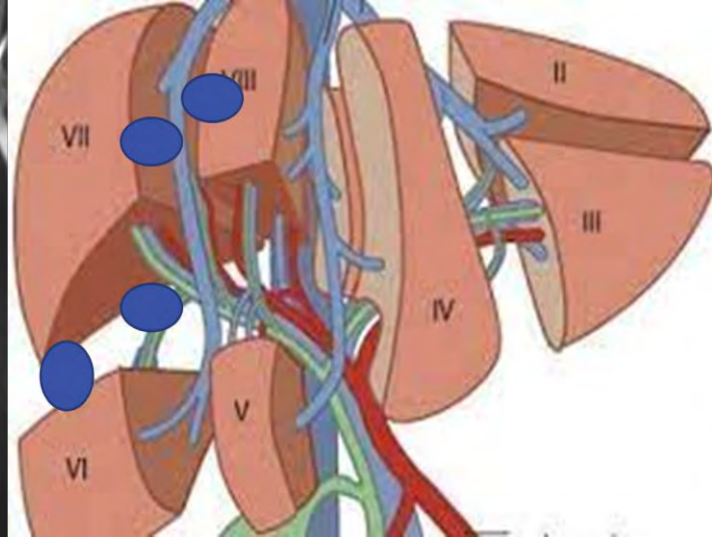
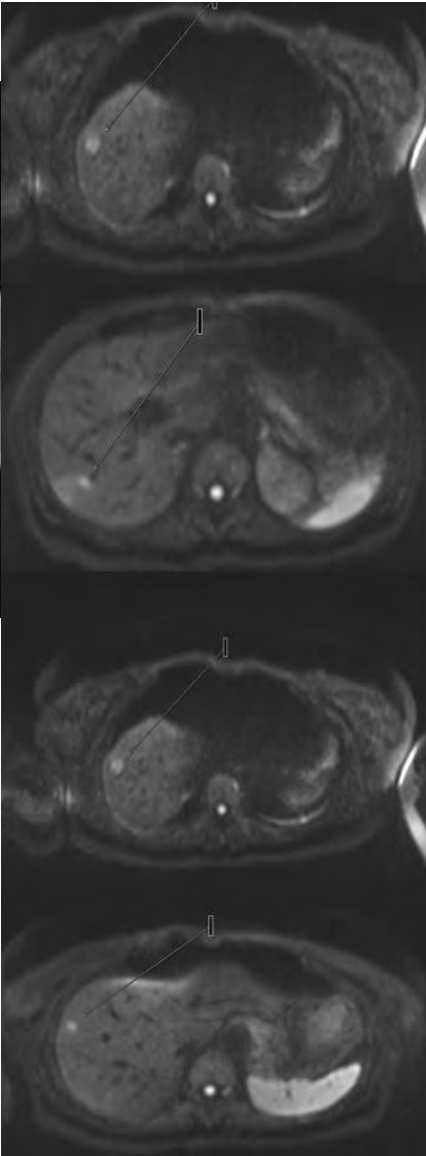
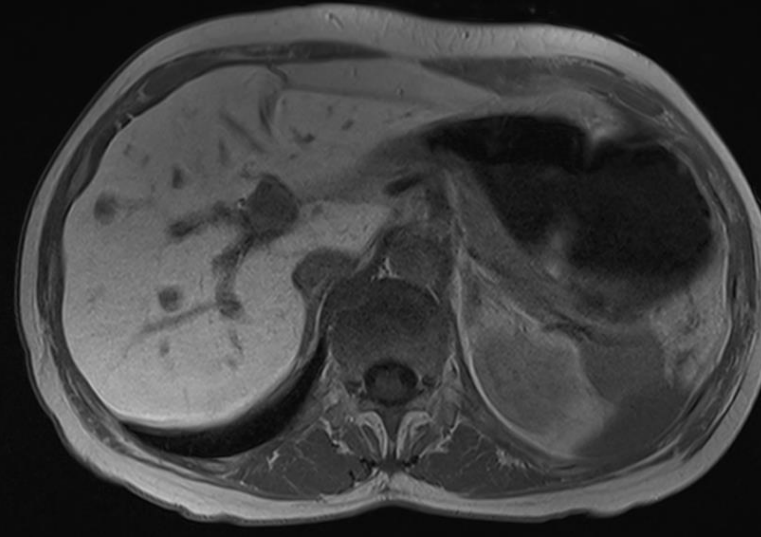
- **Synchronous liver Metastasis left colon initial presentation with occlusion**
 - First step restore bowel function

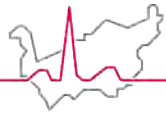




Hôpital du Valais
Spital Wallis

Cherry Picking / Swiss Cheese





Cherry Picking / Swiss Cheese

Hôpital du Valais
Spital Wallis

- **Parenchymal preserving**

- Lower morbidity/ mortality
 - Small for size
- Allows simultaneous primary colon resection
- Allows more treatment possibility if liver recurrence

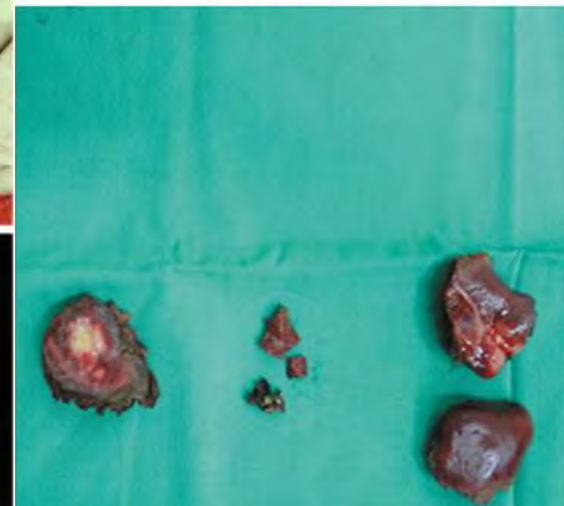
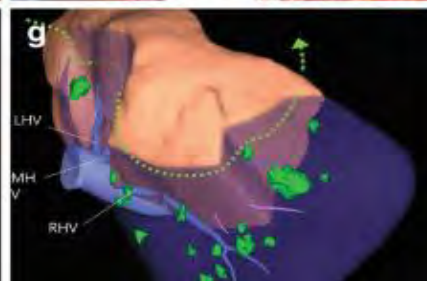
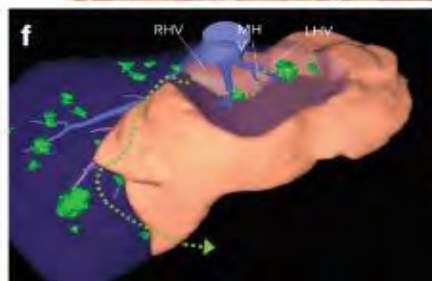
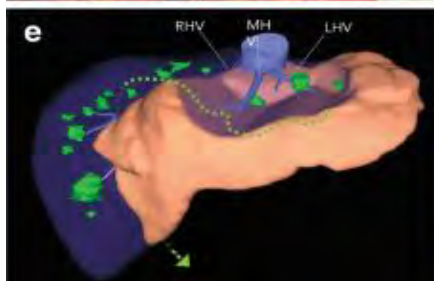
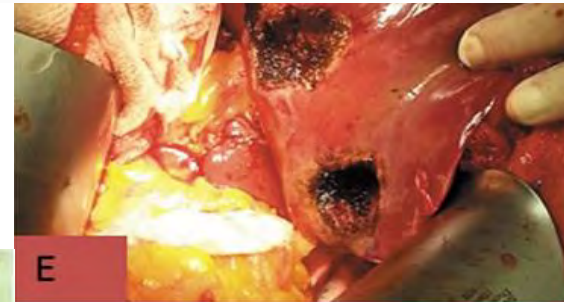


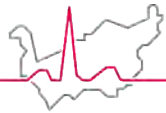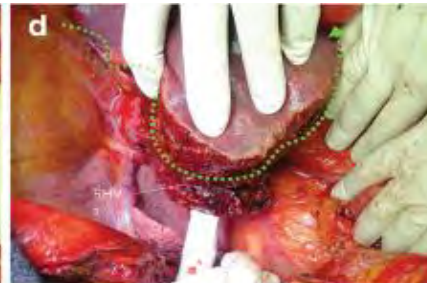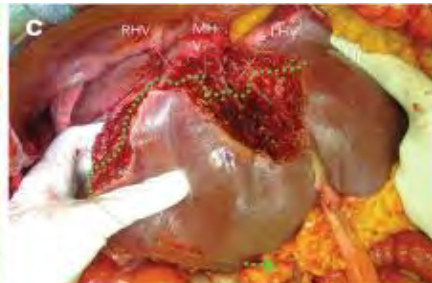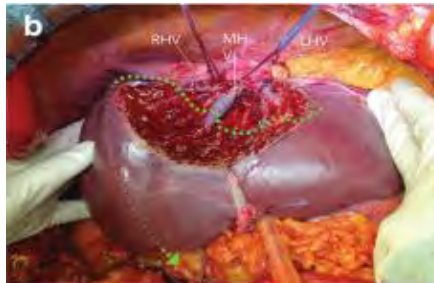
[Glissonean Pedicles Approach in Minimally Invasive Liver Surgery](#) pp 39–54 | [Cite as](#)

[Home](#) > [Glissonean Pedicles Approach in Minimally Invasive Liver Surgery](#) > Chapter

Glissonean Pedicles for Liver-Sparing Parenchymal Resection Lesson Learned from Open Surgery

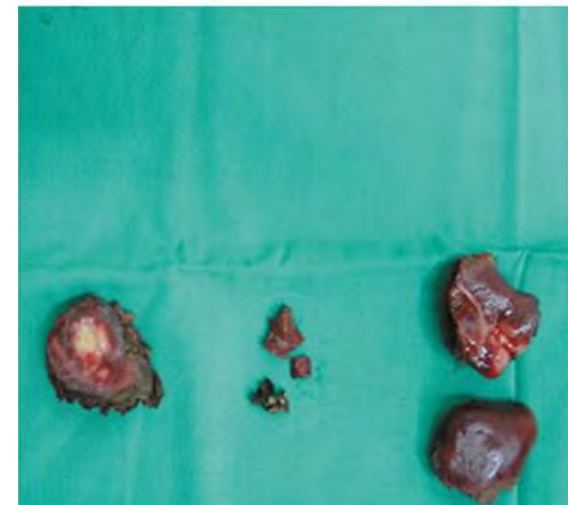
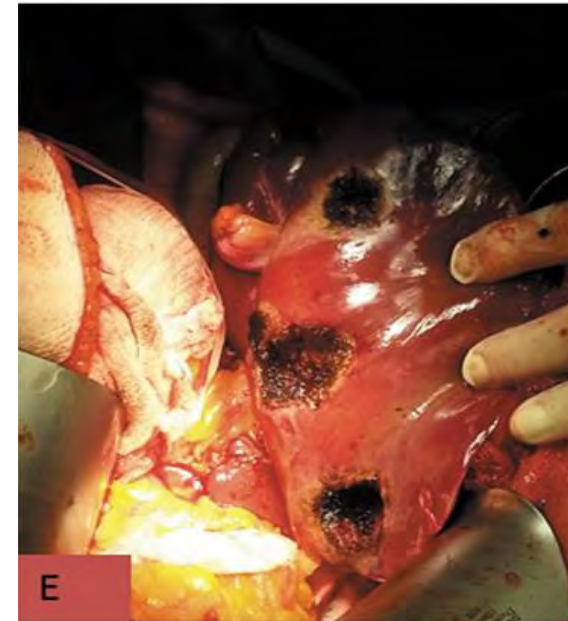
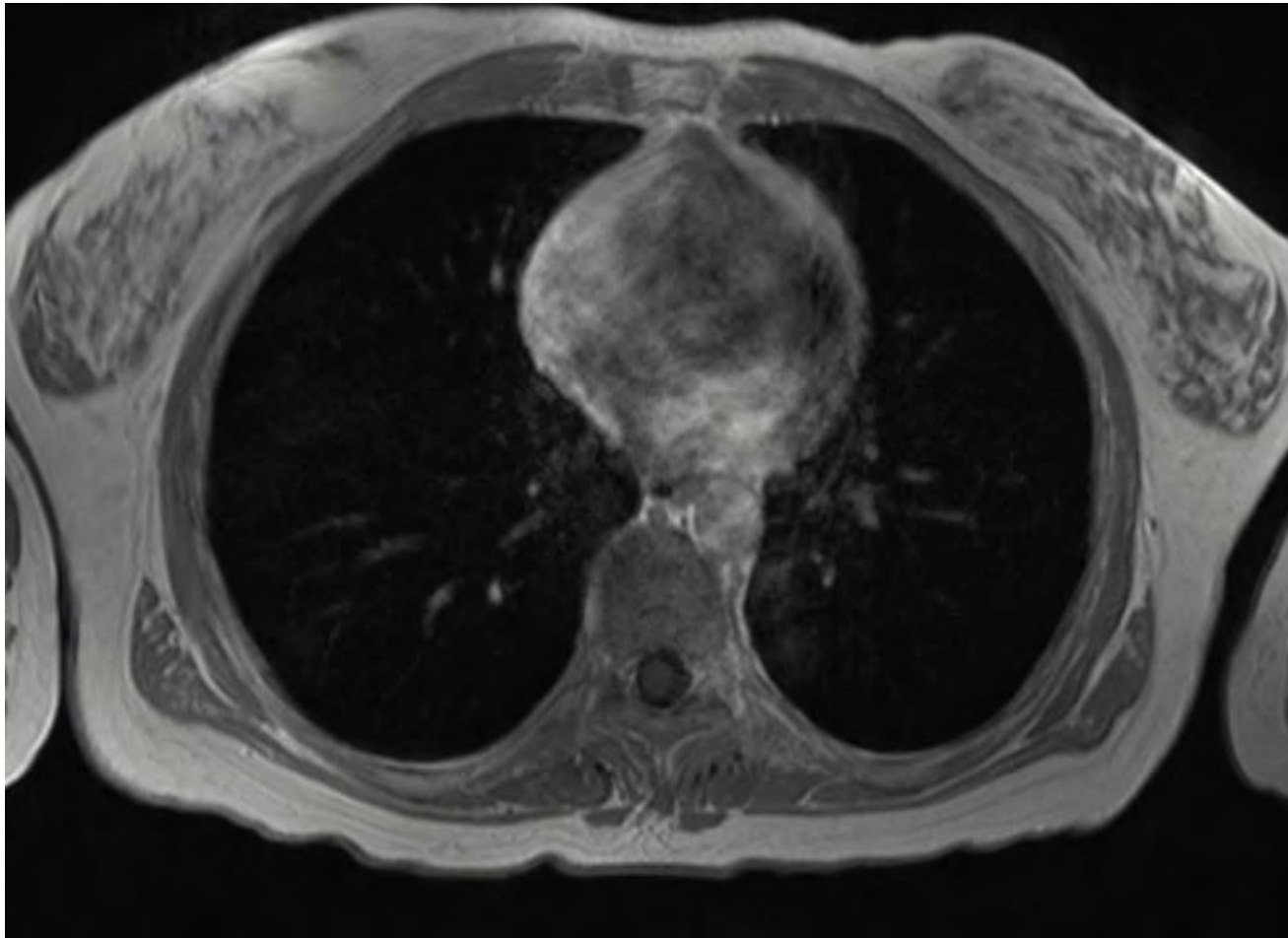
[Fabio Procopio](#) & [Guido Torzilli](#) ✉

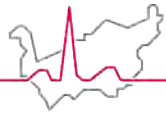




Cherry Picking / Swiss Cheese

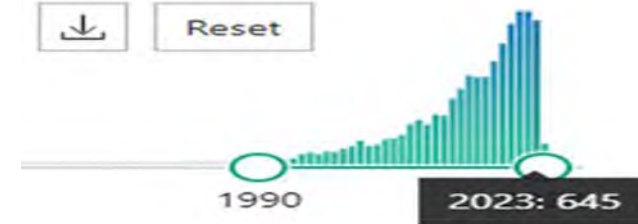
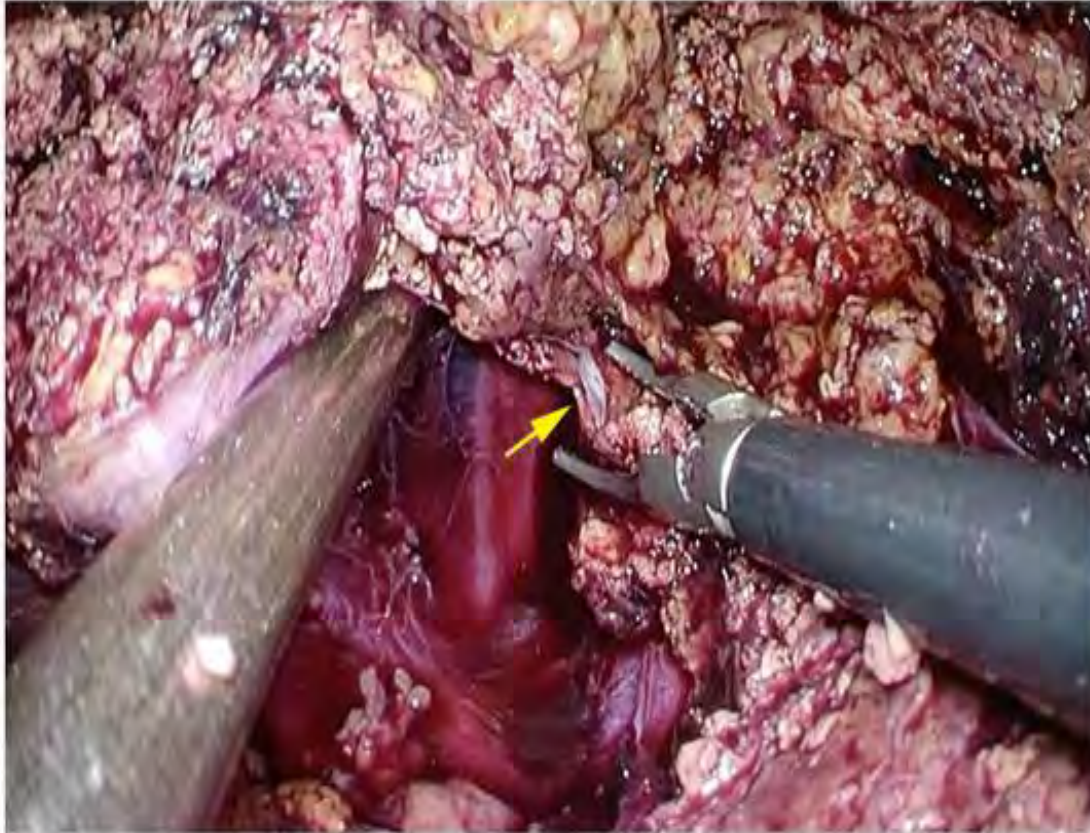
Hôpital du Valais
Spital Wallis



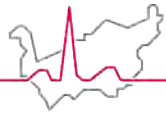


Hôpital du Valais
Spital Wallis

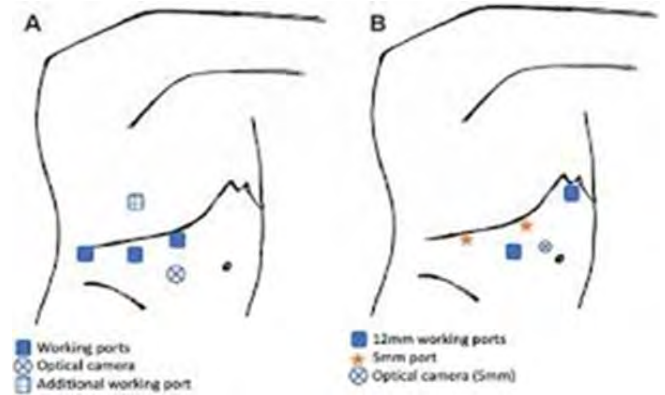
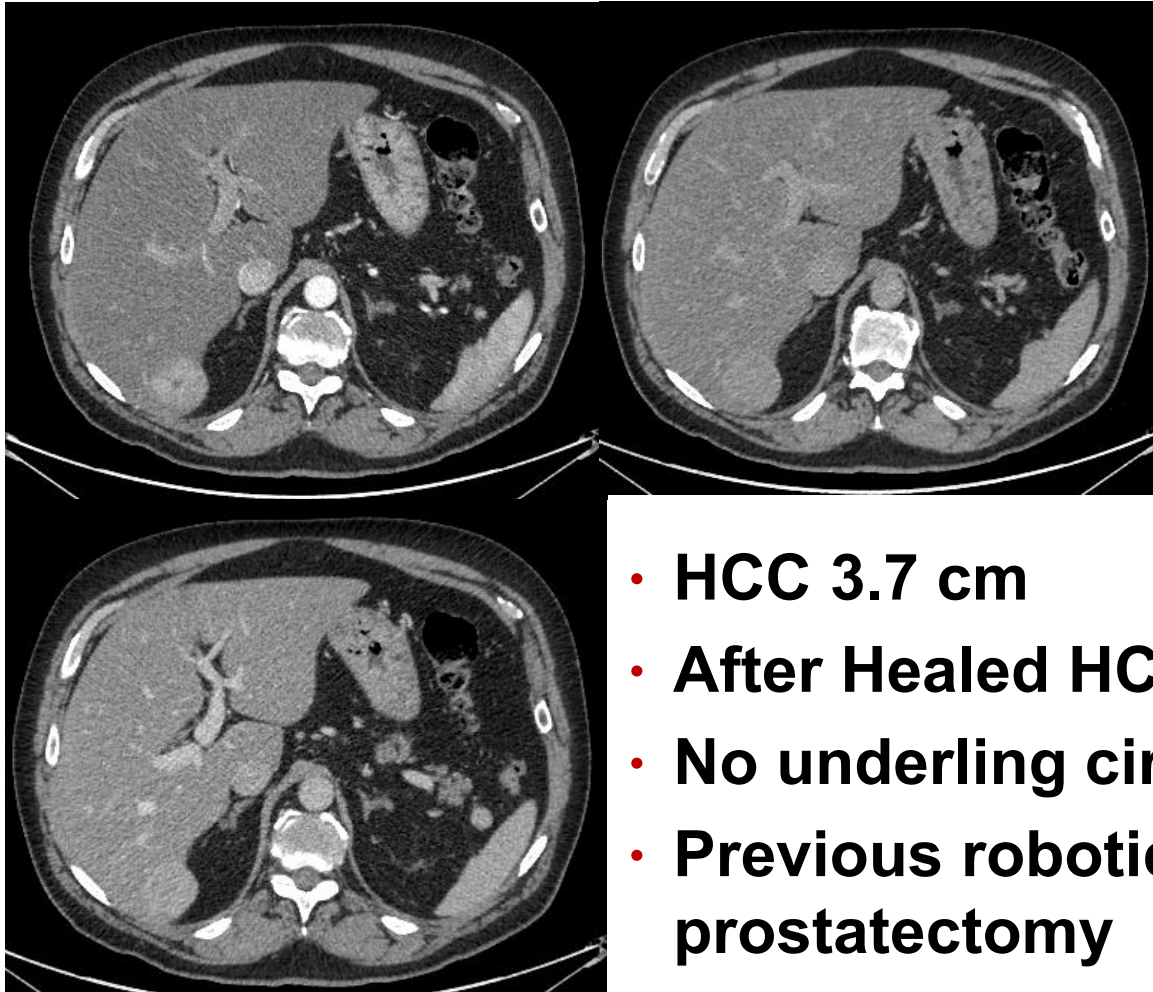
Minimally invasive liver surgery



- **First reported laparoscopic liver resection:**
 - Reich & Budin 1991
 - Gagner & Dubuc 1992
- **First robotic-assisted laparoscopic segmental hepatic resection :**
 - Giulianotti et al, in 2003
- **Firsts robotic liver transplantation**
 - Adeel Khan in 2023 Washington university

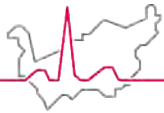


Minimally invasive liver surgery



- **HCC 3.7 cm**
- **After Healed HCV**
- **No underlying cirrhosis**
- **Previous robotic radical prostatectomy**

Minimally invasive liver surgery



Hôpital du Valais
Spital Wallis



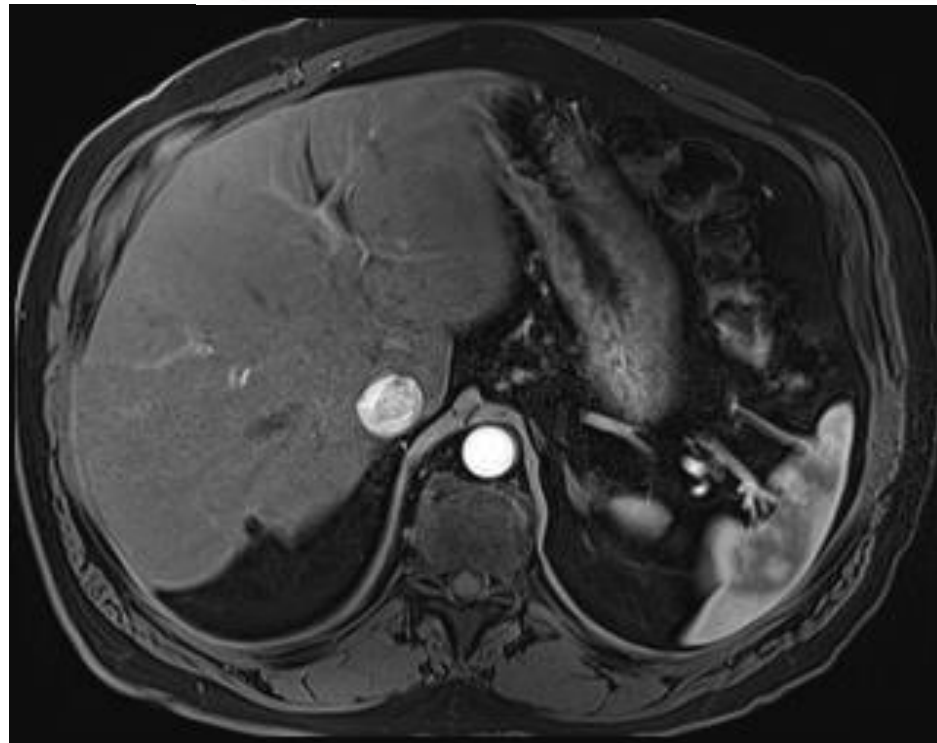
European Journal of Surgical Oncology

Volume 44, Issue 10, October 2018, Pages 1580-1587

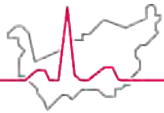


Long-term oncologic results of anatomic vs. parenchyma-sparing resection for hepatocellular carcinoma.

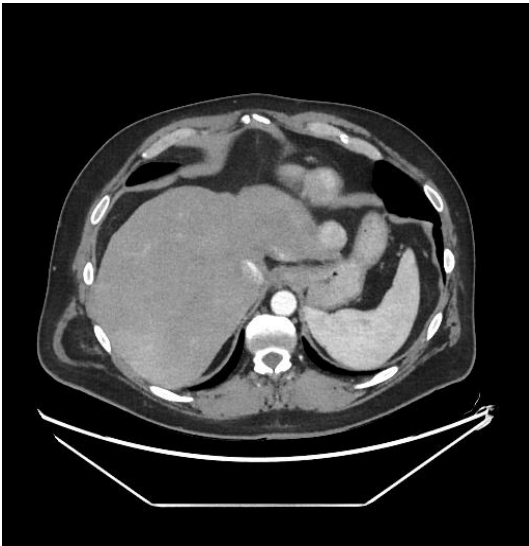
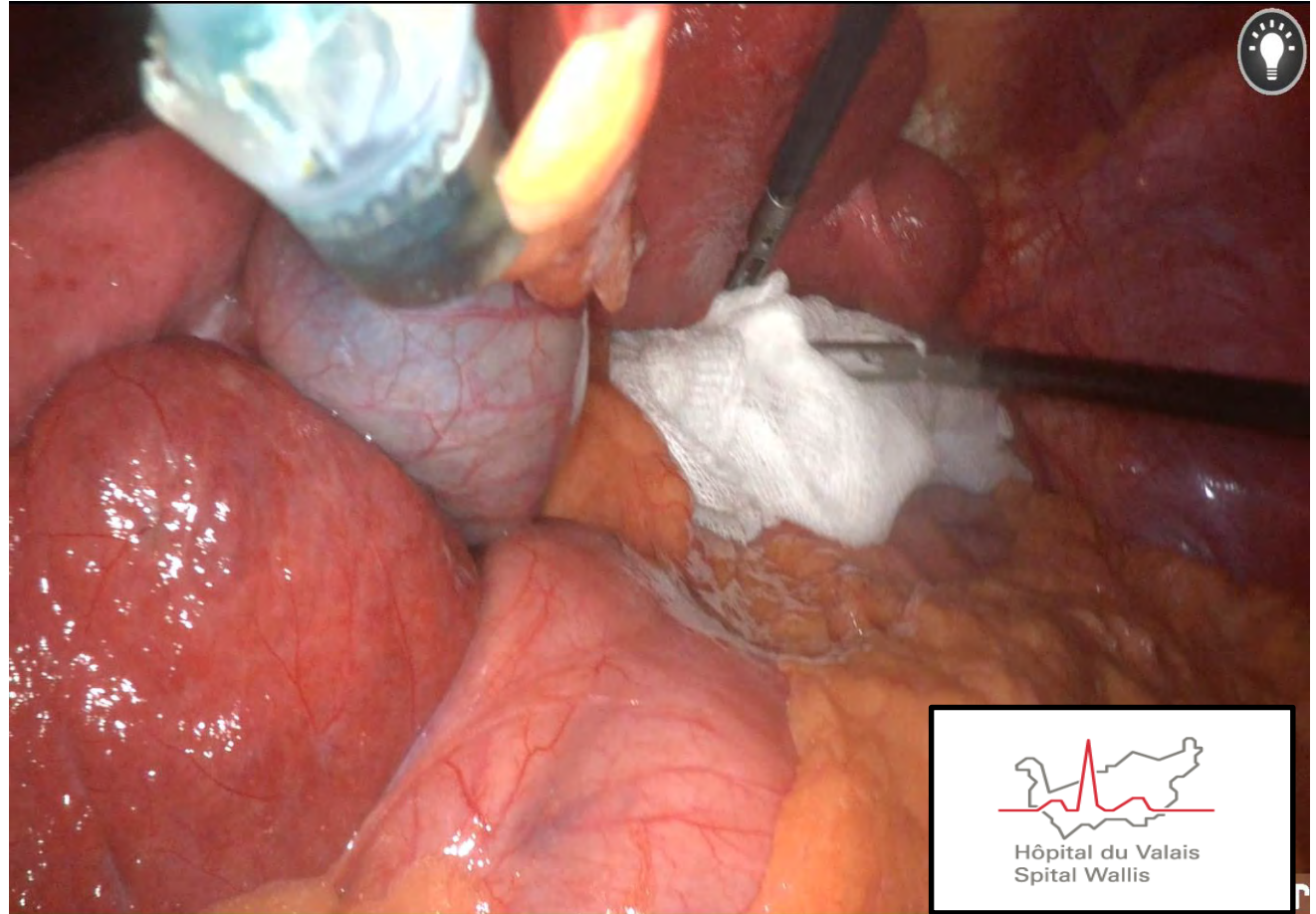
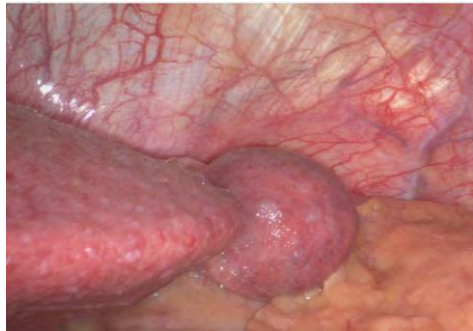Conclusions: The extent of resection did not significantly affect overall and disease-free survival while tumor characteristics and underlying liver function appeared significant determinants




Learning Minimally invasive liver surgery



Hôpital du Valais
Spital Wallis



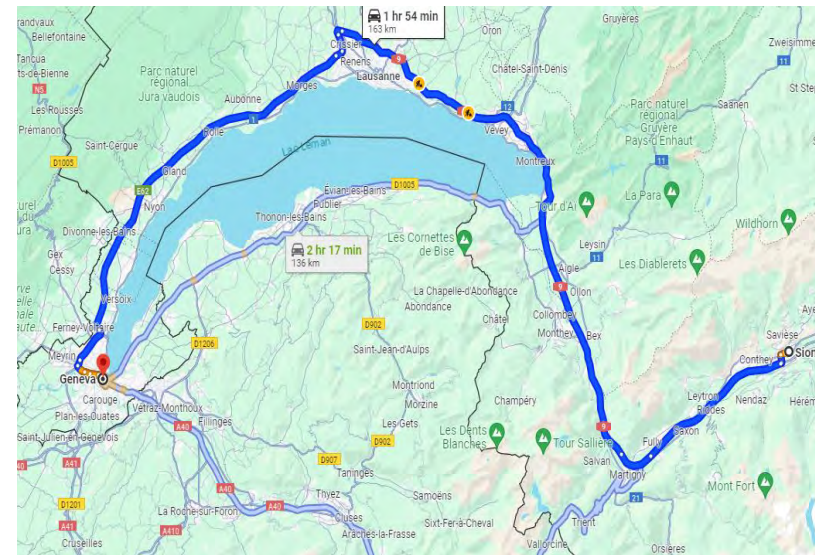
Hôpital du Valais
Spital Wallis

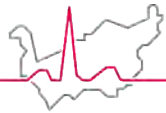


MHS Liver surgery & Geography

Hôpital du Valais
Spital Wallis

- **MHS criteria for liver surgery quite complex**
 - Localization of the lesions
 - Number of lesion
 - Contiguous segment
 - ...
- **Partnership with HUG**
 - Transplantation activity
 - Dedicated team and HBP ward
 - Same process
 - Pre-operative- surgery-post-operative- follow up
 - Medical team/oncology and neoadjuvant treatment in Sion
 - Radiological work out /Surgical & anesthesiologist consultation -> Sion
 - Surgery in HUG / GVA
 - Transfer post-operative if necessary
 - Follow up and adjuvant treatment ->Sion





Hôpital du Valais
Spital Wallis

Thank you for your Attention



- **Special Thanks**

- Center HBP team
 - **Secretary & moral support**
 - Coraline, Magali, Nensi, Marie-Laurence, Alessandra, Rosa, Sandie, Cristina
 - Martina
 - **Radiologist**
 - Christophe, Sonaz, Léonid
 - **Gastroenterologist/ hepatologist**
 - Phillippe, Christian, Phillippe,
 - **Oncologist**
 - Sandro, Irma
 - **Internal medicine**
 - Pierre-Auguste, Bruno, Jens, Niels

